Openventio PUBLISHERS

ISSN 2377-8407

SURGICAL RESEARCH

Open Journal

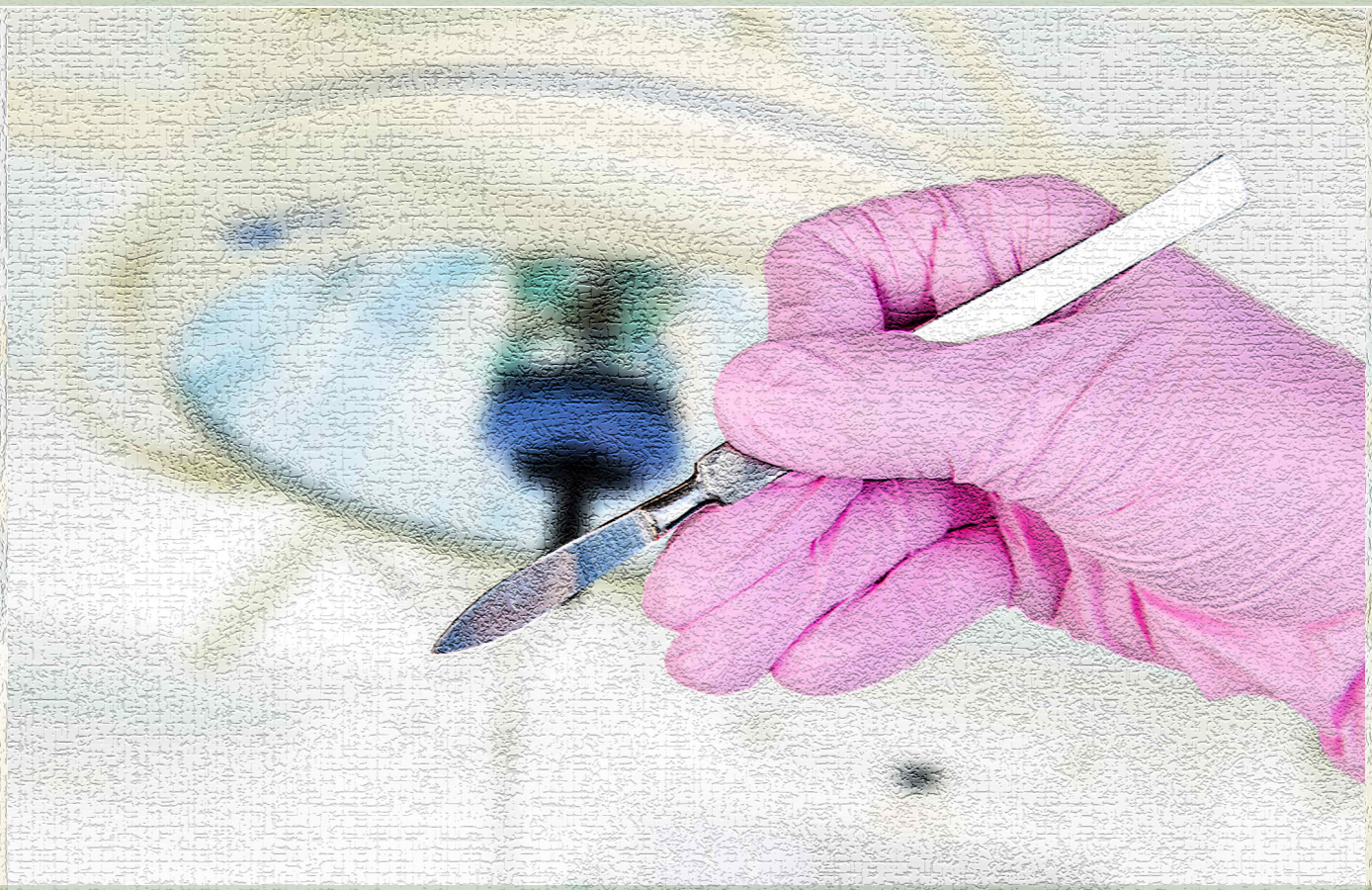

| September 2016 | Volume 3 | Issue 1 |

www.openventio.org

SURGICAL RESEARCH

Openventio PUBLISHERS

ISSN 2377-8407

Open Journal

TABLE OF CONTENTS

SURGICAL RESEARCH

Openventio PUBLISHERS

ISSN 2377-8407 Open Journal http://dx.doi.org/10.17140/SROJ-3-e002

Editorial

*Corresponding author
Alexandros Charalabopoulos, MD, MSc, PhD, MRCS, FRCS
Consultant Upper Gastrointestinal Surgeon
Department of Upper Gastrointestinal Surgery
Broomfield Hospital
Mid Essex Hospital Services NHS Trust
Court road, Chelmsford
Essex, CM1 7ET, England, UK
E-mail:acharalabopoulos@yahoo.com

Volume 3 : Issue 1
Article Ref. #: 1000SROJ3e002

Article History
Received: March 22nd, 2016
Accepted: March 29th, 2016
Published: March 29th, 2016

Citation
Rashid F, Charalabopoulos A. Laparoscopic gastrectomy for gastric cancer. *Surg Res Open J*. 2016; 3(1): e3-e5. doi: 10.17140/SROJ-3-e002

Laparoscopic Gastrectomy for Gastric Cancer

Farhan Rashid, MBBS, DM, FRCS; Alexandros Charalabopoulos, MD, MSc, PhD, MRCS, FRCS*

Department of Upper Gastrointestinal Surgery, Broomfield Hospital, Mid Essex Hospital Services NHS Trust, Chelmsford, Essex, England, UK

Gastric cancer is still the second most common cancer worldwide.[1] Perioperative combination chemotherapy conveys a significant survival benefit and is a standard of care. However, surgery still remains the mainstay of treatment.

Gastrectomy is a complex operation and carries morbidity and mortality. Increased experience with laparoscopic surgery has shown improved benefits - Minimal post-op pain, quicker mobilisation and better cosmetic results have been shown from laparoscopic gastrectomies.[2] These features are advantageous only when curability can be guaranteed as compared to that in open surgery and in some cases early gastric cancer is a good target for laparoscopic gastrectomy because the nodal metastasis is rather limited and serosal surface is intact. Recently, laparoscopic gastrectomies have been suggested for prophylactic gastrectomy performed for hereditary diffuse gastric cancer.[3] Recent meta-analysis of early gastric cancer showed a superior post-operative recovery in patients treated laparoscopically compared with those treated using an open approach.[4-6] National oesophago-gastric cancer audit results in England and Wales between April 2011 and March 2013 showed 287 gastrectomies were performed with a minimally invasive approach (includes converted) out of a total of 1806 gastrectomies. It is still 15.9% of total procedures.[7] The latest National oesophago-gastric cancer audit results in England and Wales released in January 2016, are also supportive of the same findings where minimally invasive gastrectomies (including open conversions) represented only 14.5% (246 laparoscopic *versus* 1447 open gastrectomies).[8] The Korean laparoscopic gastrointestinal surgical society has conducted a multicentre randomised controlled trial comparing laparoscopic and open surgery in the treatment of early stage gastric cancer.[9] The long-term oncological outcomes of laparoscopic gastrectomy for patients with gastric cancer have been shown to be comparable to those of open gastrectomy in a large scale, multicentre clinical study.[4] Increased overall survival rate for patients with stage IA cancer treated by laparoscopy (laparoscopy group; 95.3%, open group; 90.3%; $p<0.001$) has been shown by Kim et al.[4]

A meta-analysis of 1161 patients showed fewer overall complications following laparoscopic procedures (11%, 58/535) as compared to open gastrectomy (18%; 97/519) $p<0.001$.[10] One non-randomised control trail by Adachi et al showed no significant difference in complication rate between laparoscopic surgery (8%) and open surgery.[11]

Laparoscopic gastrectomy obviously has a steep learning curve and performing laparoscopic gastrectomies may initially take longer to do; one non-randomised control trial has shown that open procedure was 55 minutes shorter than laparoscopic.[12] In the UK, it will be challenging to perform randomised controlled trials comparing laparoscopic and open gastrectomies whilst, even today, only about 15% of gastrectomies are performed laparoscopically.[7,8] Lymph node dissection remains a challenge when it comes to laparoscopic procedures and must not be forgotten for the completeness of curative resection. Meta-analysis has shown fewer lymph nodes in laparoscopic surgery compared to open. Weighted mean difference; -4.35 nodes (95% CI -5.73 to -2.98 nodes) ($p<0.001$).[10] From OG 2014 UK audit 15.9% of minimally invasive gastrectomies also included procedures converted to open and similarly conversion from laparoscopic to open surgery has been reported between 2-3% in other studies.[7,10,12-14]

Length of hospital stay has been shown to be shortened by 5.5 days in laparoscopic gastrectomies compared to patients who underwent open gastrectomy in a meta-analysis.[10]

Intraoperative blood loss with subsequent blood transfusion has proven implication in the outcome, especially when it comes to cancer surgery and significantly lower blood loss has been shown in laparoscopic surgery as compared to open, with a weighted mean difference of 146 ml ($p<0.001$).[10]

Robotic surgery has recently been used in Upper GI surgery; limitations of laparoscopic approaches to gastrectomy can be explored using robotic approach to allow greater degree of freedom and hence improved dissection.

As per NICE guidelines (NICE interventional procedure guidance [PG269]) the laparoscopic gastrectomy is a technically demanding operation; surgeons undertaking it should have specific training and special expertise in laparoscopic surgical techniques and should perform their initial procedures with an experienced mentor. As with any upper gastrointestinal cancer, these cases should be performed in high volume centres, where the appropriate experience is available.

CONFLICTS OF INTEREST

The authors declare no conflicts of interest.

REFERENCES

1. Parkin DM, Bray FI, Devesa SS. Cancer burden in the year 2000: The global picture. *Eur J Cancer*, 2001; 37 Suppl: S4-S66. doi: 10.1016/S0959-8049(01)00267-2

2. Uyama I, Sugioka A, Fujita J, Komori Y, Matsui H, Hasumi A. Laparoscopic total gastrecomy with distal pancreatospenectomy and D2 lymphadenectomy for advanced gastric cancer. *Gastric Cancer*. 1999; 2(4): 230-234. doi: 10.1007/s101200050069

3. Rashid F, Suo C, Tan B, et al. PTU-145 Prophylactic total gastrecomt for hereditary gastric cancer syndrome. *Gut*. 2015; 64: A126. doi: 10.1136/gutjnl-2015-309861.260

4. Kim H-H, Han S-U, Kim M-C, et al. Long-Term Results of Laparoscopic Gastrectomy for Gastric. *J Clin Oncol*. 2014; 32(7): 627-633. doi: 10.1200/JCO.2013.48.8551

5. Ohtani H, Tamamori Y, Noguchi K, et al. A meta-analysis of randomised controlled trials that compared lapaoscopy-assisted and open distal gastrectomy for early gastic cancer. *J Gastrointestinal Surg*. 2010; 14: 958-964. doi: 10.1007/s11605-010-1195-x

6. Ohanti H, Tamamori Y, Noguchi K, et al. Meta-analysis of laparascopy assisted and open distal gastrectomy for gastric cancer. *J Surg Res*. 2011; 171(2): 479-485.

7. National Oesophago-gastric cancer Audit 2014. Web site. http://www.hscic.gov.uk/catalogue/PUB16020/clin-audi-supp-prog-oeso-gast-2014-rep.pdf. Accessed March 21, 2016.

8. National Oesophago-gastric cancer Audit 2015. Web site. http://www.hscic.gov.uk/catalogue/PUB19627/clin-audi-supp-prog-oeso-gast-2015-rep.pdf. Accessed March 21, 2016.

9. Kim HH, Hyung WJ, Cho GS. Morbidity and Mortality of laparoscopic gastrectomy versus open gastrectomy for gatric cancer: An interim report - A phase III multicentre, prospective, randomised Trial (KLASS Trial). *Ann Surg*. 2010; 251(3): 417-420. doi: 10.1097/SLA.0b013e3181cc8f6b

10. Hosono S, Arimoto Y, Ohtani H, Kanamiya Y. Meta-analysis of short-term outcomes after laparoscopy-assisted distal gastrectomy. *World J Gastroenterol*. 2006; 12(47): 7676-7683. doi: 10.3748/wjg.v12.i47.7676

11. Adachi Y, Shiraishi N, Shiromizu A, Bandoh T, Aramaki M, Kitano S. Laparoscopy-assisted Billroth I gastrectomy compared with conventional open gastrectomy. *Arch Surg*. 2000; 135(7): 806-810. doi: 10.1001/archsurg.135.7.806

12. Ziqiang W, Feng Q, Zhimin C, et al. Comparison of laparoscopically assisted and open radical distal gastrectomy with extended

ISSN 2377-8407 Open Journal http://dx.doi.org/10.17140/SROJ-3-e002

lymphadenectomy for gastric cancer management. *Surg Endosc*. 2006; 20: 1738-1743. doi: 10.1007/s00464-006-0031-6

13. Kitano S, Shiraishi N, Uyama I, Sugihara K, Tanigawa N; Japanese Laparoscopic Surgery Study Group. A multicenter study on oncologic outcome of laparoscopic gastrectomy for early cancer in Japan. *Ann Surg*. 2007; 245(1): 68-72. doi: 10.1097/01.sla.0000225364.03133.f8

14. Huscher CGS, Mingoli A, Sgarzini G, et al. Totally laparoscopic total and subtotal gastrectomy with extended lymph nope dissection for early and advanced gastric cancer; early an long term results of a 100 patient series. *Am J Surg*. 2007; 194(6): 839-844; discussion 844. doi: 10.1016/j.amjsurg.2007.08.037

SURGICAL RESEARCH

Openventio PUBLISHERS

ISSN 2377-8407 Open Journal http://dx.doi.org/10.17140/SROJ-3-115

Case Report

*Corresponding author
James M. Nottingham, MD, FACS
Professor of Clinical Surgery
Department of Surgery
University of South Carolina
School of Medicine, Two Medical Park
suite 300, Columbia
SC 29203, USA
Tel. (803)545-5800
Fax: (803)933-9545
E-mail: james.nottingham@uscmed.sc.edu

Volume 3 : Issue 1
Article Ref. #: 1000SROJ3115

Article History
Received: May 5th, 2016
Accepted: May 27th, 2016
Published: May 31st, 2016

Citation
Atwez A, Augustine M, Nottingham JM. Lysine pill-induced esophageal perforation. *Surg Res Open J*. 2016; 3(1): 1-3. doi: 10.17140/SROJ-3-115

Lysine Pill-Induced Esophageal Perforation

Abdelziz Atwez, MD; Matthew Augustine, BS; James M. Nottingham, MD, FACS*

Department of Surgery, University of South Carolina School of Medicine, Two Medical Park, suite 300, Columbia, SC 29203, USA

ABSTRACT

Pill-induced esophagitis is being increasingly recognized, but remains largely underreported. Most patients suffer from self-limited pain but complications like esophageal hemorrhage, stricture, perforation and even death may occur. We present a rare case of esophageal perforation secondary to pill-induced esophagitis due to ingestion of Lysine tablets.

INTRODUCTION

Since first described in 1970 pill-induced esophagitis is being increasingly recognized. Most patients suffer from self-limited pain but complications like esophageal hemorrhage, stricture, perforation and even death may occur.[1] We present a rare case of esophageal perforation secondary to pill-induced esophagitis due to ingestion of Lysine tablets.

CASE REPORT

A 71-year-old male with no past history of esophageal disease or swallowing difficulties presented to a county hospital with severe substernal chest pain and odynophagia four hours after ingesting some over-the-counter Lysine tablets. He confirmed that he took the pills while lying down with a small amount of water. The initial x-rays and lab tests were normal and the esophagogastroduodenoscopy revealed significant ulceration of his distal esophagus. The patient was admitted for parenteral hydration and pain control. He subsequently developed a large right pleural effusion over the next several hours. Computed tomography scan of his chest showed an abnormality of the distal esophagus and esophageal perforation was subsequently confirmed by Gastrograffin swallow. The patient was transferred to a tertiary care institution and underwent emergent right thoracotomy. With the delay in diagnosis and in transfer to definitive care, the patient was in florid sepsis at the time of the thoracotomy. Findings at that time were a three centimeter distal esophageal perforation, and significant contamination of the mediastinum andin the right pleural space.The perforation was debrided and closed in two layers with a muscle flap. The mediastinum was debrided as well and drains placed. Because of the tenuous closure in the face of the contamination a cervical esophagostomy was created for diversion. Postoperatively, the patient did well. He returned in three months for reversal of his cervical esophagostomy after documentation of his sealed leak on swallow study and distal esophagram.

DISCUSSION

Esophageal perforation due to pill-induced esophagitis is thought to be an unusual complication. Review of literature shows several cases of perforation reported after the use of potassium preparations, iron pills, alendronate, ibuprofen, tetracycline, doxycycline, and sustained-release sodium valproate. Cases of penetration to the left atrium and major vessels led to severe hemorrhage and death were also reported.[2]

Despite being increasingly recognized, pill-induced esophagitis is believed to be underreported with an incidence of four cases per 100,000 populations per year.[1,2] Since first described in 1970 more than 1300 cases have been reported in which more than 100 different drugs were implicated.[2]

ISSN 2377-8407 Open Journal http://dx.doi.org/10.17140/SROJ-3-115

Pill-induced esophagitis usually occurs at anatomical sites of esophageal narrowing but any area of the esophagus may be injured. The most common site of injury is the middle third of the esophagus where peristaltic amplitude is relatively low and where the esophagus may be compressed anteriorly by the aortic arch.[2] Patients with left atrial enlargement are susceptible to injury at the site where the esophagus is compressed by the left atrium.[2]

The most common medications that cause pill-induced esophagitis can be divided into four major groups based on prevalence: antibiotics such as tetracycline, doxycycline, and clindamycin accounting for about 50% of reported cases; anti-inflammatory medications such as aspirin and non-steroidal anti-inflammatory drugs were the culprit in about 20% of reported cases; bisphosphonates such as alendronate and residronate were the cause in about 15% of cases; and medications such aspotassium chloride, quinidine preparations, and iron compounds were found to be the cause in the vast majority of the other reported cases.[2]

Risk factors for pill-induced esophagitis can be patient-related, esophageal-related and drug-related. Patient factors consist of age, swallowing positioning, and amount of liquid ingested while taking medications. The risk of pill-induced esophagitis increases with age, however, this may be due to higher medication use, decreased saliva production, or a higher prevalence of anatomic abnormalities and motility disorders in the esophagus rather than physiologic changes in motility with aging. The position of the patient, and the amount of fluid ingested with the medication may be the most important determinants of the risk of pill-induced esophagitis, as significant delay in esophageal transit occurs when pills are taken in supine position without adequate amount of fluid. Ingestion of a pill immediately prior to sleep is also associated with an increased risk of pill-induced esophagitis as both salivation and swallowing frequency are markedly reduced during sleep.[2,3]

Altered esophageal anatomy may also be a risk factor for pill-induced esophagitis by increasing esophageal transit time. This is supported by the observation of a higher incidence in patients with left atrial enlargement and following thoracic surgery.[2] Esophageal stricture, dysmotility and other anatomic abnormalities such as esophageal webs and rings also increase the risk of pill-induced injury by causing a prolonged contact between the medication and the esophageal mucosa.[2-3] Although anatomic abnormalities may increase both the risk of pill-induced injury as well as the severity of the resulting complicationshowever, most cases of pill-induced esophagitis occurred in patients with no prior history of swallowing difficulties.[3]

Drug factors are comprised of the pill size, the formulation, and the intrinsic caustic or injurious characteristics of the pill being ingested. Delay in esophageal transit was observed when larger tablets were swallowed with small quantities of water.[2] Capsules are more commonly retained in the esophagus than tablets, and the sustained-release preparations are more damaging to the esophagus than standard preparation of the same medicine.[2,3]

The proposed mechanisms of direct injury by medications include the production of a caustic acidic solution, caustic alkaline solutions, hyperosmolar solutions, and the direct drug toxicity.[2,3] A pH less than 3.0 is corrosive to the human esophagus. Medications such as doxycycline, tetracycline, ascorbic acid, ferrous sulfate, and emepronium can cause local caustic injury as they have a pH less than 3 when dissolved in distilled water or saliva. Bisphosphonates produce a caustic alkaline solution. Potassium chloride creates a hyperosmolar solution in contact with esophageal mucosa leads to tissue destruction and vascular injury. Tetracycline can cause cell toxicity by inhibiting protein synthesis. And NSAIDs may cause esophagitis by disrupting the normal cytoprotective prostaglandin barrier in the stomach and esophagus.[2-3]

Patients with pill-induced esophagitis usually present with retrosternal pain, odynophagia, and less commonly dysphagia within a few hours to a month after ingesting the culprit medication. In some cases, the pain may be so severe that swallowing is impossible compromising hydration and alimentation.[2-3] Pill-induced esophagitis must be suspected when a patient presents with an abrupt retrosternal pain and odynophagia, and has a history of ingestion of potentially injurious medication. In such cases a clinical diagnosis of pill-induced esophagitis may be made.[2-3] Endoscopy is the gold standard for diagnosis of pill-induced esophagitis[4]; however, gastrograffin swallow is used when esophageal perforation is suspected.

The most important aspect of management of pill-induced esophagitis is to avoid further esophageal injury and most cases heal without intervention within a few days of discontinuing the culprit medication. Acid suppression therapy is justified when gastroesophageal reflux is documented. Patients with severe odynophagia who are unable to eat or drink may require short-term parenteral hydration or alimentation. Endoscopic dilation may be needed subsequently in patients with an esophageal stricture.[2-4] When esophageal perforation is diagnosed, then expeditious operative care with debridement, repair with muscle flap, and wide drainage is done. Lately the other option is with covered stenting to prevent the operative morbidities in select patients.

Prevention is the mainstay strategy to reduce the incidence of pill-induced esophagitis. Medications should be taken with at least 240 mL (8 oz.) of water; patients should stand or sit upright for at least 30 minutes afterwards. Medications associated with esophagitis should be avoided or used with caution in patients with predisposing factors.

Our patient suffered a rare complication of pill-induced esophagitis in that he progressed to perforation. There is no other case of Lysine pill-induced esophagitis with perforation has

ISSN 2377-8407 Open Journal http://dx.doi.org/10.17140/SROJ-3-115

been reported.

CONFLICTS OF INTEREST: None.

CONSENT

As our article did not publish any personal photo or information regarding any of the patient thus the consent is not required for the article publication.

REFERENCES

1. Kikendall JW. Pill esophagitis. *J Clin Gastroenterol*. 1999; 28(4): 298-305. Web site. http://journals.lww.com/jcge/Abstract/1999/06000/Pill_Esophagitis.4.aspx. Accessed May 4, 2016

2. Young PE, Kikendall JW. Pill-induced esophageal injury. In: Richter JE, Castell DO, eds. The Esophagus. 5th ed. Oxford, UK: Blackwell Publishing Ltd; 2012: 707-716. doi: 10.1002/9781444346220.ch38

3. Feldman M, Friedman LS, Brandt LJ. *Sleisenger and Fordtran's Gastronintestinal and Liver Disease*. 10th ed. Philadelphia, Pennsylvania, USA: Elsevier Science; 2015: 763-764.

4. Dağ MS, Öztürk ZA, Akın I, Tutar E, Çıkman Ö, Gülşen MT. Drug-induced esophageal ulcers: case series and the review of the literature. *Turk J Gastroenterol*. 2014; 25(2): 180-184. doi: 10.5152/tjg.2014.5415

SURGICAL RESEARCH

Openventio PUBLISHERS

ISSN 2377-8407 Open Journal http://dx.doi.org/10.17140/SROJ-3-116

Systematic Review

***Corresponding author**
Oliver Bellevue, MD
Section of Surgical Oncology
Swedish Medical Center
Swedish Cancer Institute
747 Broadway, 7 West, General Surgery
Seattle, WA 98122, USA
Tel. (510)301-3722
E-mail: oliver.bellevue@swedish.org

Volume 3 : Issue 1
Article Ref. #: 1000SROJ3116

Article History
Received: July 15th, 2016
Accepted: July 27th, 2016
Published: July 27th, 2016

Citation
Bellevue O, Johnson B, Feczko A, Ong F. Pancreatic cancer in the very elderly patient: Challenges and solutions. *Surg Res Open J*. 2016; 3(1): 4-12. doi: 10.17140/SROJ-3-116

Pancreatic Cancer in the Very Elderly Patient: Challenges and Solutions

Oliver Bellevue, MD*; Bennett Johnson, MD; Andrew Feczko, MD; Evan Ong, MD, MS, FACS

Section of Surgical Oncology, Swedish Medical Center, Swedish Cancer Institute, Seattle, WA, USA

ABSTRACT

Pancreatic cancer is responsible for a significant disease burden on the aging US population. The only chance at curing this highly morbid disease is surgical resection, however choosing appropriate surgical candidates in the elderly population remains challenging. We review the literature for appropriate treatment modalities to the elderly patient. Although significant literature exists in choosing appropriate surgical candidates as well as managing those not deemed fit for surgery, the medical community is not unified when approaching these patients. Further collaboration between the surgical, medical, and palliative communities will likely spawn better outcomes for less overall health care cost in the future.

KEYWORDS: Pancreatic cancer; Elderly; Palliative care; Chemotherapy.

ABBREVIATIONS: SEER: Surveillance, Epidemiology, and End Results; ASA: American Society of Anesthesiologists; ICU: Intensive Care Unit; ISGO: International Society of Geriatric Oncology; fTRST: Flemish version of the Triage Risk Screening Tool; VES-13: Vulnerable Elders Survey-13; QoL: Quality of Life; NCCN: National Comprehensive Cancer Network.

INTRODUCTION

Pancreatic cancer is the fourth leading cause of cancer related mortality with 44,000 American and 250,000 worldwide diagnoses annually.[1] A disturbing increase in the US incidence of pancreatic cancer has been noted in recent years. Surgical therapy remains the only chance at cure for early stage disease, but unfortunately only 9% of patients present with localized disease. The advanced age of diagnosis frequently complicates potential therapies due to comorbidities, frailty, or perceived risk. Although surgical morbidity has dramatically decreased, 5-year survival remains a dismal 7.8%. Current data from the Surveillance, Epidemiology, and End Results (SEER) Program reveals that only 31.7% of patients diagnosed with pancreatic cancer are under age 64, while 26.8% will be diagnosed between age 65-74, another 26.1% will be diagnosed between age 75-84, and 13.5% will be diagnosed at an age above 85. The average age at diagnosis is now 71 years of age.[2] With rising incidence in an aging population we have sought to review the best management strategy for elderly patients with pancreatic cancer.

The term "elderly" is inconsistently defined throughout the literature. Prior studies have used a range of ages from 65-90 years to demarcate "elderly", but more recent literature stresses functional status over numerical age. Several scoring systems have been developed to predict outcomes in elderly patients with cancer diagnoses and include variables such as nutritional status, laboratory values, cardiopulmonary status, timed "get up and go" testing, and American Society of Anesthesiologists (ASA) status.[3,4] Further confounding the discussion of the elderly patient with pancreatic cancer is the wide variety of pathology (pancreatic adenocarcinoma, neuroendocrine tumors, mucinous neoplasms, peri-ampullary or duodenal tumors) combined with anatomic considerations (lesions in the head *vs.* body *vs.* tail) and the implications for surgical resection, research, and outcomes. In our practice we do not define elderly at a

ISSN 2377-8407 Open Journal http://dx.doi.org/10.17140/SROJ-3-116

specific age, but rather take into account every patient's comorbidities, functional level, and nutritional status.

SURGICAL OUTCOMES

Outcomes after major abdominal operations are worse in the elderly. Two large US studies[5,6] as well as one large Australian study[7] have shown increased morbidity and mortality in older surgical patients. Interestingly, risk factors plateau at age 60, but surgical morbidity and mortality continues to increase linearly with age.[5] For unknown reasons (referral bias, surgeon hesitancy), elderly patients are operated on less than their younger counterparts; peak surgical volume occurs in the fifth decade of life.[5] The result is that many elderly patients are removed from the operative pool due to comorbidities, perceived risk, and referral basis.[8] Operative complexity has been shown to predict mortality in the elderly.[5,6] One group reported a 5% increase in mortality for every year increase above age 80.[6] Long-term outcomes are not well studied in the elderly population, but evidence regarding functional outcomes suggests a 3-6 month minimum return to baseline functional status following major abdominal surgery.[9] This has been verified in patients undergoing resection for pancreatic cancer.[10] The substantial cognitive changes associated with general anesthesia[11,12] are certainly compounded by prolonged hospitalizations or intensive care unit (ICU) stays.

Despite a tendency towards worse surgical outcomes in the elderly, surgical resection for pancreatic cancer remains the only treatment modality that offers complete cure. Surgeons have been compelled to push the age boundary in hopes of curing patients for over 60 years.[13] A PubMed search was performed using the keywords "pancreatic cancer," "elderly," "resection," and "pancreaticoduodenectomy". All publications with original data of the surgical treatment of pancreatic cancer in the elderly within the last 15 years are included in Table 1.

The shortcomings of the above studies, as a whole, are important. All are retrospective, many have a small number of participants. Additionally, few authors include details on how their cohort was or was not selected for surgery. Many authors emphasize or only report 30-day mortality. Standardized definitions of morbidity are lacking. Overall there is a trend (especially in larger studies) toward slight increase in morbidity and mortality in the elderly, although authors universally conclude that a small increase in morbidity and mortality is acceptable when weighted against the risk of not pursuing the only curative therapy.

PATIENT SELECTION AND THE NEED FOR A MULTI-DISCIPLINARY APPROACH

Careful patient selection and attention to risk factors may expand the pool of curable patients as well as limit surgical morbidity by restricting poor operative candidates. Numerous factors have been proven to predict post-operative outcomes—from concrete laboratory tests to more abstract attempts to quantify "frailty," "geriatrics," or the like. ASA class and serum albumin have been consistently identified as strong predictors of mortality in elderly patients.[6,7] Serum albumin less than 30 g/L is associated with a 4 fold increased risk of 30 day mortality.[7] These predictors have also been validated in oncology patients.[3] Various scoring systems emphasizing "frailty" (mobility, physical strength, and nutritional status) have been shown to predict length of stay, readmission, post-operative complications, cardiac events, and discharge to a skilled nursing facility.[25,26] A test of growing popularity, the timed "get up and go" test, was originally developed as a basic test of mobility.[27] In this test the administrator asks the patient to stand from a seated chair, walk 10 feet, and return to the same seated position. This simple, inexpensive test now has thorough community validation and was recently proven to predict mortality in geriatric patients receiving chemotherapy.[28] Additionally, it has also been shown to closely correlate with surgical and oncologic outcomes.[3] Another predictive formula for elderly colorectal patients has been validated and is in wide use,[4] however no scoring system yet exists specifically for patients with pancreatic neoplasm. Table 2 summaries known risk factors that are germane to the pre-operative evaluation of elderly patients.

Given the variety of scoring systems, their lack of validation in this disease, and their inconsistent use, the role of geriatric medicine should not be underplayed. The International Society of Geriatric Oncology (ISGO) is the leading authority on health care screening and optimization in elderly oncology. Although not specific to pancreatic cancer, this review board demonstrated that peri-operative assessment with a comprehensive geriatric assessment, as well as assessments of fatigue and performance status and an anesthesiologist's evaluation of operative risk could predict a 50% increase in the relative risk of post-operative complications and extended hospital stays.[29] Subsequently, ISGO published updated consensus guidelines. This 2014 review found that geriatric assessment in older oncology patients had multiple benefits, including the ability to predict outcomes after oncologic treatment, identify those patients who were more likely to have adverse outcomes after treatment, and prevent under or over treating this population.[30]

In spite of the benefits, referring all elderly patients to a geriatrician may prove too large a burden for the health care system to carry. Furthermore, without a consistent definition of elderly due to the heterogeneity of this population, the ISGO also endorses the use of screening tools to identify patients most in need of a geriatric assessment. Numerous screening tools exist, but the most studied are the G8, Flemish version of the Triage Risk Screening Tool (fTRST) and Vulnerable Elders Survey-13 (VES-13). Of these, the most studied and highest sensitivity (80%) of detecting a patient who would benefit from a comprehensive geriatric assessment was the G8. Importantly, screening tools have never been demonstrated to confer the benefits of a comprehensive geriatric assessment, but in resource-poor practices these tools may offer a cost-effective middle ground.[31,32]

ISSN 2377-8407 Open Journal http://dx.doi.org/10.17140/SROJ-3-116

Study	Total N	Age	Summary of Findings	Median Survival	Long term Survival
Bathe et al[14]	70	75	No difference in 30-day mortality (8.5%), significant increase in morbidity in elderly (31% v 63%). Measured endpoints for morbidity: gastric atony, pancreatic fistula, intra abdominal abscess, biliary fistula, wound infection, line sepsis, urinary tract infection, gastrointestinal bleeding, bladder injury, pneumothorax, suppurative thrombophlebitis, pyleophlebitis, chylous ascites, respiratory insufficiency, pneumonia, cardiovascular, multiple organ failure, hyperglycemia, pulmonary embolism, renal insufficiency, seizure, delirium, gout.	24 months for patients less than 75 years old, and 9 months in those over 75.	5-year survival: 23% in patients less than 75 years old and 31% in those over 75.
Hodul et al[15]	122	70	No difference in 30-day mortality (only one death in the younger cohort) or morbidity. Measured endpoints for morbidity: wound infection, abscess, anastomotic leak, cardiac, urinary tract infection.	Not reported.	Not reported.
Brozetti et al[16]	166	70	Significant increase in 30-day mortality (4% v 11%) and significant increase in morbidity (46% v 49%) in the elderly. Measured endpoints for morbidity: pancreatic fistula, pancreatitis, biliary fistula, delayed gastric emptying, post-operative bleeding, sepsis, wound infection, urinary tract infection, pneumonia, cardiac, renal, or cerebrovascular disease.	Not reported.	Not reported.
Makary et at[17]	2698	80/90	Significant increase in 30-day mortality and morbidity for patients aged 80-90 compared to those less than 80, but not significant for those greater than 90. Measured endpoints for morbidity: reoperation, small bowel obstruction, ulcer, delayed gastric emptying, pancreatic fistula, pancreatitis, cardiac, pneumonia, sepsis, intra-abdominal abscess, lymph leak, cholangitis, bile leak, wound infection.	40 months for patients less than 80 years old, 19 months for patients 80-90, and 15 months for patients over 90.	5-year survival: 43.1% for patients less than 80 years old, 24.4% in those 80-90 and 0% in those over 90.
Scurtu et al[18]	70	75	No difference in 30-day mortality (0% v 6.2%) or morbidity. Measured endpoints for morbidity: pancreatic fistula, delayed gastric emptying, bleeding, intestinal occlusion, intraabdominal collection, abdominal wall sepsis, ulcer, biliary stenosis, sepsis, urinary infection, pneumopathy and pleural effusion, neurologic, pulmonary, diarrhea, thrombophlebitis.	20 months for all patients.	3-year survival: 33.1% in patients less than 75 years old and 27.7% in those over than 75.
Finlayson et al[19]	23,518	70/80	Significant increase in 30-day mortality with increased age for all groups (7% v 9% v 16%). Morbidity not reviewed.	Not reported.	5-year survival: 16% in patients less than 80 years old, 11% in those over 80.
Riall et al[20]	3,736	60/70/80	Significant increase in 30-day mortality with increased age for all groups (2% v 6% v 7% v 11%). Morbidity not reviewed.	Not reported.	Not reported.
Ito et al[21]	98	75	No difference in 30-day mortality (0% v 3.2%) or morbidity. Measured endpoints for morbidity: pancreatic fistula, delayed gastric emptying, liver abscess, wound infection, intra abdominal bleeding, respiratory insufficiency, intra abdominal collection, sepsis, bile leakage, or gastrointestinal bleeding.	Not reported.	3-year survival: 65.9% for patients less than 75 years old and 50.5% for those over 75.
Oguro et al[22]	561	80	Significant increase in morbidity and significant decrease in median survival. Measured endpoints for morbidity: pancreatic fistula, delayed gastric emptying, abscess, hemorrhage, pneumonia, ascites.	65 months in patients less than 80 years old and 43 months in those over 80.	5-year survival: 51% in patients less than 80 years old and 46% in those over 80.
Frakes et al[23]	193	70	No difference in mortality or morbidity. Measured endpoints for morbidity: Pancreatic leak, gastrojejunostomy leak, atrial fibrillation, pulmonary embolus, abscess, wound infection, wound dehiscence, anastomotic bleed, stricture, pancreatic fistula, enterocutaneous fistula, peritonitis.	23 months in patients less than 70 years old, 23.4 months in those 70–75, 16.1 months those 76–80, and 18.7 months in those over 80.	5-year survival: 26.7% in patients less than 70 years old, 23% in those 70–75, 0% in those 76–80, and 15.4% in those over 80.
Zhang et al[24]	216	70	No difference in mortality or morbidity. Measured endpoints for morbidity: Delayed gastric emptying, pancreatic fistula, abscess, pleural effusion, cardiac, pulmonary, neurologic, urinary infections.	14 months in those less than 70 and 20 months in those over 70.	5-year survival: 14.8% in those less than 70 and 21.6% in those over 70.

Table 1: Outcomes after pancreatic resection in the elderly patient.

ISSN 2377-8407 Open Journal http://dx.doi.org/10.17140/SROJ-3-116

Study	Age	Risk Factor	Study Endpoint
Hamel et al[6]	80	Most predictive factors: ASA, albumin, emergency surgery, functional status, and blood urea nitrogen.	30-day mortality
McNicol et al[7]	70	ASA, albumin, emergency surgery, renal impairment, respiratory insufficiency.	30-day mortality
Makary et al[26]	65	Weight loss, grip strength, exhaustion, activity level, walking speed.	Post-operative complications, length of stay, and discharge to a skilled nursing facility.
Robinson et al[25]	65	Frailty score, defined by: Katz score, Timed up-and-go, Charlson Index, anemia, mini-cog, albumin, and a fall within 6 months.	Length of stay and 30-day readmission rate.

Table 2: Preoperative evaluation of the elderly surgical candidate.

Although the ISGO offers several compelling reviews, geriatric medicine is rarely involved or done so in a fragmented way. Even specific to the elderly patient with pancreatic cancer this discipline predicts major complications, including longer hospital stays, ICU admissions, and readmission.[33] Similarly, palliative care is also involved relatively late—after treatment failures have occurred. This may partially result from physicians consistently overestimating life expectancy in oncology patients.[34] In a recent study only 52% of patients with advanced stage pancreatic adenocarcinoma had received a palliative care consultation; however, this consult is associated with decreased use of chemotherapy within 30 days of death, a lower risk of ICU admission, multiple emergency department visits, and multiple hospitalizations.[35] This study was not focused solely on the elderly patient. Some authors have advocated that palliative care consults should replace surgical resection (although we find this approach rather limiting in good-risk operative candidates). Patients on palliative care were found to spend 50% of what is required for surgical treatment with estimated quality-adjusted life years equivalent across groups.[36] No centers have yet reported an automatic palliative care consult triggers at the time of diagnosis for patients of any age. Based on the above studies, such an early multi-specialty approach would likely decrease cost, increase surgical utility, and provide better outcomes. Shared decision making will become mandatory as cost containment becomes a higher priority.

PALLIATIVE INTERVENTIONS IN THE ELDERLY

Chemotherapy

Eighty percent of patients of any age present with anatomically unresectable disease, a trend that will continue unless an early tumor marker is found. Chemotherapy is considered first line treatment for un-resectable disease. Current National Comprehensive Cancer Network (NCCN) guidelines for pancreatic adenocarcinoma recommend single agent gemcitabine for patients with poor performance status or intensive chemotherapy regimen of 5-fluorouracil, oxaliplatin, irinotecan, leucovorin (FOLFIRINOX) for those with a good performance status.[37] Data for chemotherapy is directly applicable to the elderly population; in the hallmark study comparing FOLFIRINOX to gemcitabine for metastatic pancreatic cancer, 76 out of 342 patients were 65 years or older.[38]

A recent Cochrane Review questions the necessity for aggressive 5-fluorouracil based regimens (such as FOLFIRINOX) with the finding that mono-agent gemcitabine is non-inferior to 5-fluorouracil for survival. Gemcitabine also had significant clinical benefit given limited side effects and therefore has been used frequently in the elderly population. Additional agents in combination with either gemcitabine or 5-fluorouracil have shown some improvement in early response rates, but this has not translated into a survival benefit.[39] In the elderly patient, the best chemotherapy regimen will certainly focus on the quality of life (QoL), limiting toxicity, and reducing disease associated pain.

A PubMed search using the terms “pancreatic cancer,” “chemotherapy,” and “elderly” failed to reveal any study that prospectively assigned patients to a chemotherapeutic regimen based on their age or performance status; however, several studies have demonstrated the safety, feasibility, and survival advantage of chemotherapy when used in the palliative setting for the elderly patient. These studies are reviewed in Table 3.

Overall these studies have relatively few participants, although outcomes and conclusions are similar. Most investigators prohibit patients with poor performance status or a large number of comorbidities from receiving chemotherapy. Notably, when elderly patients with worse performance status are treated with palliative chemotherapy the median survival appears quite similar (3.9 months) compared to studies utilizing best supportive care (2.3-4.2 months). This comparison may prove flawed as many patients treated with best supportive care were assigned that modality based on poor performance status, frailty, or family’s wishes. Currently, there is no evidence to support or deny the use of chemotherapy over best supportive care in elderly patients with poor performance status. Additional studies that distinguish between locally advanced and metastatic disease are warranted as patients with metastatic disease appear to have significantly worse survival.

BILIARY AND GASTRIC OUTLET BYPASS

The traditional operation to treat biliary and gastric outlet obstruction, an open double bypass, is of declining use given advances in endoscopic stenting.[47] The morbidity associated with a large operation is balanced against the durability of endoscopic interventions in patients with limited longevity. Biliary obstruction, with resultant puritis and fat mal-absorption, has been the topic of five randomized controlled studies. A recent meta-anal-

ISSN 2377-8407 Open Journal http://dx.doi.org/10.17140/SROJ-3-116

Study	Total N	Cohort	Variable	Median Survival (months)	Comments
Maréchal et al[40]	99	Elderly <70 *vs* >70	Age	7.9 *vs* 7.2	Gemcitabine and gemcitabine-based regimens. No significant difference in survival between groups.
Locher et al[41]	38	Elderly >70	None (feasibility study)	7 *vs* 10	Longer survival in patients receiving second line 5-FU
Yamagishi et al[42]	66	<70 v >70 v best supportive care	Gemcitabine v best supportive care	10.2 *vs* 9.6 *vs* 4.2	No significant survival difference regardless of age when treated with gemcitabine
Matsumoto[43]	68	Elderly >65 years of age	Gemcitabine v best supportive care	7.6 *vs* 2.3	36% of patients treated with gemcitabine had grade 3 or 4 toxicity
Hentic et al[44]	38	Elderly >75 years of age	Gemcitabine v best supportive care	9.1 *vs* 2.9	23% of patients treated with gemcitabine had grade 3 toxicity
Berger et al[45]	53	Elderly >70 years of age	Any agent, ECOG<1 v ECOG>2	7.8 *vs* 3.9	81% gemcitabine monotherapy
Oziel-Taieb et al[46]	107	Elderly > 75	Locally advanced v metastatic disease	9.1 *vs* 4.7	Gemcitabine, 5-FU & cisplatin, or 5-FU alone

Table 3: Palliative chemotherapy in the elderly patient with pancreatic cancer. Survival differences are statically significant except where noted.

ysis examined these five studies and included 191 patients in the surgical arm and 188 patients in the endoscopic arm.[48] The review concludes that surgical palliation was safe, more durable than endoscopic treatment and should be offered first line to patients who are low surgical risk. A serious limitation of the above meta-analysis is the age of the studies included, with publication dates of 1986, 1988, 1989, 1994, and 2006. Advances in surgical, endoscopic, and anesthetic technique may well influence this older data. For example, self-expanding metal stents and concomitant duodenal stents are two technologies that have only recently been developed and were not reflected in older trials. Additionally, none of this data specifically targets the elderly patient.

A Cochrane review from 2006, found metal stents to have improved durability over older plastic stents.[49] The overall durability of surgical bypass was also reaffirmed. Similar results have been found in a more recent, albeit small retrospective study of 55 elderly patients (over 65 years old).[50] These authors similarly conclude that surgical palliation is superior to endoscopic stenting for malignant biliary obstruction even in spite of any increased surgical risk related to advanced age. They report no difference in morbidity or mortality, but better quality of life and longer survival in open bypass patients (mean 290 compared to 150 days).

Gastric outlet obstruction is a less frequent, but equally unpleasant complication with associated nausea, vomiting, cachexia and fatigue. Open gastrojejunostomy is the historic gold standard with newer modalities including laparoscopic gastrojejunostomy and endoscopic stenting. Survival averages 82 days once malignant gastric outlet obstruction presents.[51] Studies uniformly indicate that endoscopic intervention results in decreased initial hospital stay and cost with a faster return to oral intake.[52-54] Unfortunately the durability of endoscopic intervention is again inferior with frequent rate of re-intervention (11% *vs.* 48%, $p<0.01$).[37] Stenting has been proven to be equivalent in the elderly population with equal rates of success, complications, and oral intake.[55] For both biliary and gastric outlet obstruction, low risk patients should give consideration to surgical bypass, while those with decreased fitness or limited predicted survival should opt for endoscopic intervention.

PALLIATIVE WHIPPLE

Offering a palliative pancreaticoduodenectomy was popularized by a retrospective study from John's Hopkins in 1996 that found a survival advantage (mean 15 compared to 12 months) for patients that underwent pancreaticoduodenectomy with positive margins compared to patients that underwent a double bypass procedure at the time of an intended curative pancreaticoduodenectomy.[56] This notion has met significant controversy with multiple subsequent studies summarized in a meta-analysis that focused quality of life after each operation.[57] This meta-analysis concludes that patients recover faster from a double bypass procedure. In spite of a non-significant trend toward decreased survival in the double bypass group (6 *vs.* 7 months, $p=0.09$), this earlier return to baseline function and fewer long-term symptoms (specifically diarrhea) resulted in an overall improved quality of life in the bypass group. The controversy continues as newer studies delineate between an R1 resection (microscopically positive margins), an R2 (grossly positive margins) resection and a double bypass.[58] This data also concludes that a double bypass is associated with the least morbidity and the shortest survival. These authors have also concluded that this increased survival advantage (14-18 months compared to 9-13 months) outweighs the increased morbidity. R2 resections are associated with especially poor outcomes (7-10 month survival) and increased morbidity. Unfortunately, these studies appear underpowered as evidenced by the large range in survival after purportedly similar operations.None of these operations have been specifically studied in the elderly patient.

A NOVEL THERAPY: IRREVERSIBLE ELECTROPORATION

A novel therapy for the treatment of locally advanced disease is irreversible electroporation, or "NanoKnife," which acts through local electrical ablation of tumor cells. Early, small

ISSN 2377-8407 Open Journal http://dx.doi.org/10.17140/SROJ-3-116

studies are very promising. The largest to date includes 54 patients in a prospective, multicenter trial who underwent irreversible electroporation that were matched to 85 patients with similar pancreatic disease burden who underwent standard of care chemo-radiation. Overall survival improved in patients undergoing irreversible electroporation (20 *vs.* 13 months, p=0.03).[59] The oldest patient in this cohort was 80 years old, range 45-80 years. Another reported cohort includes 14 patients who underwent percutaneous irreversible electroporation. No deaths were attributed to the procedure; however two patients had complications (pneumothorax and pancreatitis). Two of these patients subsequently underwent R0 resection (Microscopically negative margins).[60] Ultrasound has also been successfully used to localize and treat with irreversible electroporation.[61] In this study, five patients safely underwent irreversible electroporation and one went on to have R0 pancreaticoduodenectomy. Due to its potential as a minimally invasive therapy, irreversible electroporation may gain significantly utility in the elderly population if larger studies continue to validate its efficacy.

PAIN MANAGEMENT

Severe abdominal pain is one of the most devastating consequences of end stage pancreatic cancer. As early as 1969, attempts at chemical splanchnicectomy have been described, although it was not until 1993 that the first prospective, randomized, double-blind, placebo controlled trial was preformed in this population.[62] Patients receiving alcohol ablation scored significantly lower on pain scores at 2, 4, 6 months and on final assessment. The average age of these patients was 64 years old. Another randomized trial compared celiac block to medical pain management (non-steroidal anti-inflammatory drugs and opiates) and found a significant decrease in analgesic use (specifically opiates) in patients receiving chemical splanchnicectomy.[63] The mean age of this study was 67 years in the group receiving the block and 63 years in the pharmacologic group. In contrast, a similarly designed trial found no significant decrease in the use of opiates, no difference in quality of life, or difference in survival, although patients undergoing splanchnicectomy did score consistently lower on pain scores.[64] A Cochrane review was undertaken in 2011 to determine the overall efficacy of this treatment and its influence on opiate use. A total of six randomized control trials (358 participants) were identified. The results found a statistically significant decrease not only in pain scores but also in opiate use in patients undergoing splanchnicectomy.[65] Given the minimal reported side effects of chemical splanchnicectomy and the large potential benefit of decreasing opiate use in the vulnerable elderly population this treatment modality ought be employed when feasible.

RESOURCE UTILIZATION

Hospital resource utilization for elderly patients undergoing pancreaticoduodenectomy has only once been studied in the literature.[66] *Via* single institution retrospective review, patients undergoing pancreaticoduodenectomy were compared based on age (less than 70 years old, 70-80 years, and greater than 80 years). This study included 99 total patients. Both groups aged 70-80 and above 80 were associated with significantly higher hospital charges. The youngest cohort charged $22,073 less than the middle cohort and $34,373 less than those patients over 80 years of age. This initial study bears further validation and may well prove highly significant as health care cost meets containment.

CONCLUSION

The best management strategy for elderly patients with pancreatic cancer depends on a variety of factors including pathology, anatomic resectability, patient comorbidity and overall fitness. When and how to best proceed with resection is best determined as a multidisciplinary conversation with early inclusion of palliative care, geriatrics, oncology and surgical specialties. Innovative prognostic factors such as genomic sequencing will play a larger role in counseling and treating the elderly patient. Improvements in determining a patient's true "age" reflected by the ability to safely undergo a major operation or chemotherapy treatment must be made. Although a wealth of data exists, it remains underutilized. Mitigating peri-operative risk will undoubtedly call for increasing consolidation of patients into high volume centers to allow for standardization and access to all needed specialties. Palliation will best be treated in a similar setting. Increasing demands on the health care system are guaranteed with the aging US population.

CONFLICTS OF INTEREST

None of the above authors have any disclosures.

REFERENCES

1. Yeo TP, Lowenfels AB. Demographics and epidemiology of pancreatic cancer. *Cancer J*. 2012; 18(6): 477-484. doi: 10.1097/PPO.0b013e3182756803

2. Surveillance Epidemiology and End Results. SEER Fact Sheets: Pancreas. Web site. http://seer.cancer.gov/. Accessed July 15, 2016.

3. Huisman MG, Audisio RA, Ugolini G, et al. Screening for predictors of adverse outcome in onco-geriatric surgical patients: A multicenter prospective cohort study. *Eur J Surg Oncol*. 2015; 41(7): 844-851. doi: 10.1016/j.ejso.2015.02.018

4. Tran Ba Loc P, du Montcel ST, Duron JJ, et al. Elderly POSSUM, a dedicated score for prediction of mortality and morbidity after major colorectal surgery in older patients. *Br J Surg*. 2010; 97(3): 396-403. doi: 10.1002/bjs.6903

5. Turrentine FE, Wang H, Simpson VB, Jones RS. Surgical risk factors, morbidity, and mortality in elderly patients. *J Am Coll Surg*. 2006; 203(6): 865-877. doi: 10.1016/j.jamcoll-

surg.2006.08.026

6. Hamel MB, Henderson WG, Khuri SF, Daley J. Surgical outcomes for patients aged 80 and older: morbidity and mortality from major noncardiac surgery. *J Am Geriatr Soc*. 2005; 53(3): 424-429. doi: 10.1111/j.1532-5415.2005.53159.x

7. McNicol L, Story DA, Leslie K, et al. Postoperative complications and mortality in older patients having non-cardiac surgery at three Melbourne teaching hospitals. *Med J Aust*. 2007; 186(9): 447-452. Web site. https://www.mja.com.au/journal/2007/186/9/postoperative-complications-and-mortality-older-patients-having-non-cardiac. Accessed July 14, 2016

8. Bilimoria KY, Mentrem DJ, Ko CY, Stewart AK, Winchester DP, Talamonti MS. National failure to operate on early state pancreatic cancer. *Ann Surg*. 2007; 246(2): 173-180. doi: 10.1097/SLA.0b013e3180691579

9. Lawrence VA, Hazuda HP, Cornell JE, et al. Functional independence after major abdominal surgery in the elderly. *J Am Coll Surg*. 2004; 199(5): 762-772. doi: 10.1016/j.jamcollsurg.2004.05.280

10. Lightner AM, Glasgow RE, Jordan TH, et al. Pancreatic resection in the elderly. *J Am Coll Surg*. 2004; 198(5): 697-706. doi: 10.1016/j.jamcollsurg.2003.12.023

11. Deiner S, Silverstein JH. Postoperative delirium and cognitive dysfunction. *Br J Anaesth*. 2009; 103(Suppl 1): i41-i46. doi: 10.1093/bja/aep291

12. Abildstrom H, Rasmussen LS, Rentowl P, et al. Cognitive dysfunction 1-2 years after non-cardiac surgery in the elderly. ISPOCD group. International Study of Post-Operative Cognitive Dysfunction. *Acta Anaesthesiol Scand*. 2000; 44(10): 1246-1251. doi: 10.1034/j.1399-6576.2000.441010.x

13. Ferfuson G. Pancreatico-duodenectomy: Operation on two elderly patients. *Br Med J*. 1954.

14. Bathe OF, Levi D, Caldera H, et al. Radical resection of periampullary tumors in the elderly: Evaluation of long-term results. *World J Surg*. 2000; 24(3): 353-358. doi: 10.1007/s002689910056

15. Hodul P, Tansey J, Golts E, et al. Age is not a contraindication to pancreaticoduodenectomy. *Am Surg*. 2001; 67(3): 270-275. Web site. http://search.proquest.com/openview/878ad5e8812d22375068082eb6aae539/1?pq-origsite=gscholar. Accessed July 15, 2016

16. Brozzetti S, Mazzoni G, Miccini M, et al. Surgical treatment of pancreatic head carcinoma in elderly patients. *Arch Surg*. 2006; 141(2): 137-142. doi: 10.1001/archsurg.141.2.137

17. Makary MA, Winter JM, Cameron JL, et al. Pancreaticoduodenectomy in the very elderly. *J Gastrointest Surg*. 2006; 10(3): 347-356. doi: 10.1016/j.gassur.2005.12.014

18. Scurtu R, Bachellier P, Oussoultzoglou E, Rosso E, Maroni R, Jaeck D. Outcome after pancreaticoduodenectomy for cancer in elderly patients. *Gastrointest Surg*. 2006; 10(6): 813-822. doi: 10.1016/j.gassur.2005.12.010

19. Finlayson E, Fan Z, Birkmeyer JD. Outcomes in octogenarians undergoing high-risk cancer operation: A national study. *J Am Coll Surg*. 2007; 205(6): 729-734. doi: 10.1016/j.jamcollsurg.2007.06.307

20. Riall TS, Reddy DM, Nealon WH, Goodwin JS. The effect of age on short-term outcomes after pancreatic resection: A population-based study. *Ann Surg*. 2008; 248(3): 459-467. doi: 10.1097/SLA.0b013e318185e1b3

21. Ito Y, Kenmochi T, Irino T, et al. The impact of surgical outcome after pancreaticoduodenectomy in elderly patients. *World J Surg Oncol*. 2011; 9: 102. doi: 10.1186/1477-7819-9-102

22. Oguro S, Shimada K, Kishi Y, et al. Perioperative and long-term outcomes after pancreaticoduodenectomy in elderly patients 80 years of age and older. *Langenbecks Arch Surg*. 2013; 398(4): 531-538. doi: 10.1007/s00423-013-1072-7

23. Frakes JM, Strom T, Springett GM, et al. Resected pancreatic cancer outcomes in the elderly. *J Geriatr Oncol*. 2015; 6(2): 127-132. doi: 10.1016/j.jgo.2014.11.005

24. Zhang D, Gao J, Li S, et al. Outcome after pancreaticoduodenectomy for malignancy in elderly patients. *Hepatogastroenterology*. 2015; 62(138): 451-454. Web site. http://europepmc.org/abstract/med/25916080. Accessed July 14, 2016

25. Robinson TN, Wu DS, Pointer L, Dunn CL, Cleveland JC Jr, Moss M. Simple frailty score predicts postoperative complications across surgical specialties. *Am J Surg*. 2013; 206(4): 544-550. doi: 10.1016/j.amjsurg.2013.03.012

26. Makary MA, Segev DL, Pronovost PJ, et al. Frailty as a predictor of surgical outcomes in older patients. *J Am Coll Surg*. 2010; 210(6): 901-908. doi: 10.1016/j.jamcollsurg.2010.01.028

27. Podsiadlo D, Richardson S. The timed "Up & Go": A test of basic functional mobility for frail elderly persons. *J Am Geriatr Soc*. 1991; 39(2): 142-148. doi: 10.1111/j.1532-5415.1991.tb01616.x

28. Soubeyran P, Fonck M, Blanc-Bisson C, et al. Predictors of early death risk in older patients treated with first-line chemotherapy for cancer. *J Clin Oncol*. 2012; 30(15): 1829-1834. doi: 10.1200/JCO.2011.35.7442

29. Audisio RA, Pope D, Ramesh HS, et al. Shall we operate? Preoperative assessment in elderly cancer patients (PACE) can help. A SIOG surgical task force prospective study. *Crit Rev Oncol Hematol*. 2008; 65(2): 156-163. doi: 10.1016/j.critrevonc.2007.11.001

30. Wildiers H, Heeren P, Puts M, et al. International Society of Geriatric Oncology consensus on geriatric assessment in older patients with cancer. *J Clin Oncol*. 2014; 32(24): 2595-2603. doi: 10.1200/JCO.2013.54.8347

31. Decoster L, Van Puyvelde K, Mohile S, et al. Screening tools for multidimensional health problems warranting a geriatric assessment in older cancer patients: An update on SIOG recommendations. *Ann Oncol*. 2015; 26(2): 288-300. doi: 10.1093/annonc/mdu210

32. Sullivan R, Alatise OI, Anderson BO, et al. Global cancer surgery: Delivering safe, affordable, and timely cancer surgery. *Lancet Oncol*. 2015; 16(11): 1193-1224. doi: 10.1016/S1470-2045(15)00223-5

33. Dale W, Hemmerich J, Kamm A, et al. Geriatric assessment improves prediction of surgical outcomes in older adults undergoing pancreaticoduodenectomy: A prospective cohort study. *Ann Surg*. 2014; 259(5): 960-965. doi: 10.1097/SLA.0000000000000226

34. Amano K, Maeda I, Shimoyama S, et al. The accuracy of physicians' clinical predictions of survival in patients with advanced cancer. *J Pain Symptom Manage*. 2015; 50(2): 139-146. doi: 10.1016/j.jpainsymman.2015.03.004

35. Jang RW, Krzyzanowska MK, Zimmermann C, Taback N, Alibhai SMH. Palliative care and the aggressiveness of end-of-life care in patients with advanced pancreatic cancer. *J Natl Cancer Inst*. 2015; 107(3): pii: dju424. doi: 10.1093/jnci/dju424

36. Ljungman D, Hyltander A, Lundholm K. Cost-utility estimations of palliative care in patients with pancreatic adenocarcinoma: A retrospective analysis. *World J Surg*. 2013; 37(8): 1883-1891. doi: 10.1007/s00268-013-2003-z

37. National Comprehensive Cancer Network (NCCN). 2015. http://www.nccn.org/professionals/physician_gls/pdf/pancreatic.pdf

38. Conroy T, Desseigne F, Ychou M, et al. FOLFIRINOX versus ge38. mcitabine for metastatic pancreatic cancer. *N Engl J Med*. 2011; 364: 1817-1825. doi: 10.1056/NEJMoa1011923

39. Gurusamy KS, Kumar S, Davidson BR, et al. Resection versus other treatments for locally advanced pancreatic cancer. *Cochrane Database Syst Rev*. 2014; 2: CD010244. doi: 10.1002/14651858.CD010244.pub2

40. Maréchal R, Demols A, Gay F, et al. Tolerance and efficacy of gemcitabine and gemcitabine-based regimens in elderly patients with advanced pancreatic cancer. *Pancreas*. 2008; 36(3): e16-e21. doi: 10.1097/MPA.0b013e31815f3920

41. Locher C, Fabre-Guillevin E, Brunetti F, et al. Fixed-dose rate gemcitabine in elderly patients with advanced pancreatic cancer: An observational study. *Crit Rev Oncol Hematol*. 2008; 68(2): 178-182. doi: 10.1016/j.critrevonc.2008.06.010

42. Yamagishi Y, Higuchi H, Izumiya M. Gemcitabine as first-line chemotherapy in elderly patients with unresectable pancreatic carcinoma. *J Gastroenterol*. 2010; 45(11): 1146-1154. doi: 10.1007/s00535-010-0258-9

43. Matsumoto K, Miyake Y, Kato H, et al. Effect of low-dose gemcitabine on unresectable pancreatic cancer in elderly patients. *Digestion*. 2011; 84(3): 230-235. doi: 10.1159/000330384

44. Hentic O, Dreyer C, Rebours V, et al. Gemcitabine in elderly patients with advanced pancreatic cancer. *World J Gastroenterol*. 2011; 17(30): 3497-3502. doi: 10.3748/wjg.v17.i30.3497

45. Berger AK, Abel U, Komander C, et al. Chemotherapy for advanced pancreatic adenocarcinoma in elderly patients (≥70 years of age): A retrospective cohort study at the National Center for Tumor Diseases Heidelberg. *Pancreatology*. 2014; 14(3): 211-215. doi: 10.1016/j.pan.2014.03.004

46. Oziel-Taieb S, Faure M, Gilabert M, et al. Treatment of pancreatic adenocarcinoma in elderly patients over 75 years of age: A retrospective series of 129 patients. *J Gastrointest Cancer*. 2015; 47(1): 15-19. doi: 10.1007/s12029-015-9774-4

47. Kneuertz PJ, Cunningham SC, Cameron JL, et al. Palliative surgical management of patients with unresectable pancreatic adenocarcinoma: Trends and lessons learned from a large, single institution experience. *J Gastrointest Surg*. 2011; 15(11): 1917-1927. doi: 10.1007/s11605-011-1665-9

48. Glazer ES, Hornbrook MC, Krouse RS. A meta-analysis of randomized trials: immediate stent placement vs. surgical bypass in the palliative management of malignant biliary obstruction. *J Pain Symptom Manage*. 2014; 47(2): 307-314. doi: 10.1016/j.jpainsymman.2013.03.013

49. Moss AC, Morris E, MacMathuna P. Palliative biliary stents for obstructing pancreatic carcinoma. *Cochrane Database Syst Rev*. 2006; (1): CD004200. doi: 10.1002/14651858.CD004200.pub2

50. Hwang SI, Kim HO, Son BH, et al. Surgical palliation of unresectable pancreatic head cancer in elderly patients. *World J Gastroenterol*. 2009; 15(8): 978-982. doi: 10.3748/wjg.15.978

51. van Hooft JE, Dijkgraaf MG, Timmer R, et al. Independent

predictors of survival in patients with incurable malignant gastric outlet obstruction: A multicenter prospective observational study. *Scand J Gastroenterol.* 2010; 45(10): 1217-12122. doi: 10.3109/00365521.2010.487916

52. Fiori E, Lamazza A, Volpino P, et al. Palliative management of malignant antro-pyloric strictures. Gastroenterostomy vs. endoscopic stenting. A randomized prospective trial. *Anticancer Res.* 2004; 24(1): 269-271.

53. Mehta S, Hindmarsh A, Cheong E, et al. Prospective randomized trial of laparoscopic gastrojejunostomy versus duodenal stenting for malignant gastric outflow obstruction. Surg Endosc. 2006; 20(2): 239-242. doi: 10.1007/s00464-005-0130-9

54. Jeurnink SM, Steyerberg EW, van Hooft JE, et al. Surgical gastrojejunostomy or endoscopic stent placement for the palliation of malignant gastric outlet obstruction (SUSTENT study): A multicenter randomized trial. *Gastrointest Endosc.* 2010; 71(3): 490-499. doi: 10.1016/j.gie.2009.09.042

55. Mansoor H, Zeb F. Enteral stents are safe and effective to relieve malignant gastric outlet obstruction in the elderly. *J Gastrointest Cancer.* 2015; 46(1): 42-47. doi: 10.1007/s12029-014-9675-y

56. Lillemoe KD, Cameron JL, Yeo CJ, et al. Pancreaticoduodenectomy. Does it have a role in the palliation of pancreatic cancer? *Ann Surg*. 1996; 223(6): 718-725. Web site. http://www.ncbi.nlm.nih.gov/pmc/articles/PMC1235219/. Accessed July 15, 2016

57. Schniewind B, Bestmann B, Kurdow R, et al. Bypass surgery versus palliative pancreaticoduodenectomy in patients with advanced ductal adenocarcinoma of the pancreatic head, with an emphasis on quality of life analyses. *Ann Surg Oncol.* 2006; 13(11): 1403-1411. doi: 10.1245/s10434-006-9172-z

58. Tol JA, Eshuis WJ, Besselink MG, et al. Non-radical resection versus bypass procedure for pancreatic cancer - a consecutive series and systematic review. *Eur J Surg Oncol*. 2015; 41(2): 220-227. doi: 10.1016/j.ejso.2014.11.041

59. Martin RC, McFarland K, Ellis S, et al. Irreversible electroporation in locally advanced pancreatic cancer: potential improved overall survival. *Ann Surg Oncol*. 2013; 20(Suppl 3): S443-S449. doi: 10.1245/s10434-012-2736-1

60. Narayanan G, Hosein PJ, Arora G, et al. Percutaneous irreversible electroporation for downstaging and control of unresectable pancreatic adenocarcinoma. *J Vasc Interv Radiol.* 2012; 23(12): 1613-1621. doi: 10.1016/j.jvir.2012.09.012

61. Månsson C, Bergenfeldt M, Brahmstaedt R, et al. Safety and preliminary efficacy of ultrasound-guided percutaneous irreversible electroporation for treatment of localized pancreatic cancer. *Anticancer Res.* 2014; 34(1): 289-293. Web site. http://ar.iiarjournals.org/content/34/1/289.long. Accessed July 15, 2016.

62. Lillemoe KD, Cameron JL, Kaufman HS, et al. Chemical splanchnicectomy in patients with unresectable pancreatic cancer. A prospective randomized trial. *Ann Surg.* 1993; 217(5): 447-455. Web site. http://www.ncbi.nlm.nih.gov/pmc/articles/PMC1242819/. Accessed July 15, 2016.

63. Okuyama M, Shibata T, Morita T, et al. A comparison of intraoperative celiac plexus block with pharmacological therapy as a treatment for pain of unresectable pancreatic cancer. *J Hepatobiliary Pancreat Surg.* 2002; 9(3): 372-375. doi: 10.1007/s005340200042

64. Wong GY, Schroeder DR, Carns PE, et al. Effect of neurolytic celiac plexus block on pain relief, quality of life, and survival in patients with unresectable pancreatic cancer: a randomized controlled trial. *JAMA.* 2004; 291(9): 1092-1029. doi: 10.1001/jama.291.9.1092

65. Arcidiacono PG, Calori G, Carrara S, et al. Celiac plexus block for pancreatic cancer pain in adults. *Cochrane Database Syst Rev.* 2011; (3): CD007519. doi: 10.1002/14651858.CD007519.pub2

66. Langan R, Huang C, Mao W, et al. Pancreaticoduodenectomy hospital resource utilization in octogenarians. *Am J Surg.* 2016; 211(1): 70-75. doi: 10.1016/j.amjsurg.2015.04.014

SURGICAL RESEARCH

Openventio PUBLISHERS

ISSN 2377-8407 Open Journal http://dx.doi.org/10.17140/SROJ-3-117

Case Report

*Corresponding author
Raúl González-García, MD, PhD, FEBOMFS
Consultant Surgeon
Department of Oral and Maxillofacial Surgery
University Hospital Infanta Cristina
Calle Los Yébenes 35, 8C
28047, Madrid, Spain
E-mail: raulmaxilo@gmail.com

Volume 3 : Issue 1
Article Ref. #: 1000SROJ3117

Article History
Received: July 20th, 2016
Accepted: August 17th, 2016
Published: August 17th, 2016

Citation
Villanueva-Alcojol L, Laza LR, González FG, González-García R. Single-step primary reconstruction after complex fronto-orbital brown tumor resection using computed-designed peek implant. *Surg Res Open J*. 2016; 3(1): 13-19. doi: 10.17140/SROJ-3-117

Single-Step Primary Reconstruction After Complex Fronto-Orbital Brown Tumor Resection Using Computed-Designed Peek Implant

Laura Villanueva-Alcojol, MD, PhD[1]; Luis Ruiz Laza, MD[1]; Fernando González González, MD[2]; Raúl González-García, MD, PhD, FEBOMFS[1*]

[1]*Department of Oral and Maxillofacial Surgery, University Hospital Infanta Cristina, Badajoz, Spain*

[2]*Department of Ophtalmology, University Hospital Infanta Cristina, Badajoz, Spain*

ABSTRACT

The authors describe a patient with secondary hyperparathyroidism (HPT) who had development of a brown tumors (BTs) of the superior orbit and frontal calvarium with subsequent visual impairment. One-step surgery involving wide en-bloc resection of the entire tumor and immediate fronto-orbital reconstruction with a custom-made polyetheretherketone (PEEK) implant was planned. Using a PEEK implant a one-step reconstruction of the fronto-orbital region was achieved obtaining symmetry and good functional results, reducing operative time and avoiding donor site morbidity.

KEYWORDS: Oral squamous cell carcinoma; Management; Human papilloma virus; Sentinel node biopsy; Tissue shrinkage; Radiotherapy; Neck dissection; Salvage surgery; Prognosis, QoL; Iberic graft; Facial transplantation.

INTRODUCTION

Brown tumors are uncommon bony lesions caused by rapid osteoclastic activity and peritrabecular fibrosis. They are known to occur only in the setting of HPT, as a direct result of the effect of parathyroid hormone on bone tissue. For years, these lesions have been recognized in primary HPT. However, brown tumors have also been reported in patients with severe HPT secondary to chronic renal failure, especially those on long-term hemodialysis.[1]

The ribs, clavicles, pelvic girdle, spine, tibia, humerus and mandible are their preferred location. While the mandible is the most frequently involved bone in the head and neck region,[2-8] fronto-orbital involvement is extremely rare, with only a few cases in the literature.[9-17] Moreover, reconstruction of this region is complex and remains a challenge for maxilofacial surgeon.

We describe a patient with secondary HPT who had development of a brown tumor of the superior orbit and frontal calvarium with subsequent visual impairment. One-step surgery involving wide en-bloc resection of the entire tumor and immediate fronto-orbital reconstruction with a custom-made PEEK implant was planned.

CASE REPORT

A 27-year-old white woman with medical hystory significant for chronic renal failure on hemodialysis presented with painful progressive proptosis, downward displacement and limited upgaze of her left globe, and a palpable fronto-temporal mass beneath the left frontal scalp. The swelling was firm and painless to the touch (Figure 1).

ISSN 2377-8407 Open Journal http://dx.doi.org/10.17140/SROJ-3-117

Figure 1: Pre-operative clinical photograph of patient.

On ophtalmic examination, visual acuity was 20/50 OD and 10/200 OI. Intraocular pressure was 14/16 mmHg. Left blepharoptosis and edema, proptosis of the globe, and an associated enlarging subcutaneous mass of the left frontal scalp were noted. Left hypotropia and restriction of left upgaze were present. The left macula demonstrated horizontal choroidal folds mainly in the superotemporal region. The left optic disc was pale with sharp margins more evident nasally. Pre-retinal haemorrhages secondary to compression were also evident.

Computed tomography (CT) revealed a heterogeneous mass of left frontal area with erosion of inner and outer table of the skull and roof of the orbit. The lesion extended into the superior orbit, causing depression of globe. No brain edema was present. Magnetic resonance imaging (MRI) showed a large heterogeneously enhacing extra-axial mass centered at the left frontal calvarium and roof of the left orbit. The mass showed areas of internal hemorrhage (Figure 2). CT and MRI also demostrated the presence of 2 more asymptomatic tumors with similar characteristics in maxilla and mandible.

The initial treatment involved the correction of hyperparathyroidism, which usually leads to tumor regression. The patient underwent a total parathyroidectomy identified in the usual location by scintigraphy, with auto-transplantation of parathyroid tissue. However, the orbital lesion progressively increased in size and there was not regression in the proptosis of the right eye, as confirmed by a CT performed 6 months after parathyroidectomy. We did not observe changes in maxilla and mandible lesions and they remained asymptomatic.

The resection of the fronto-orbital mass was planned with virtual pre-operative surgery that allowed manufacturing of a specific implant to accurately fit to the defect during the one stage surgery (Figure 3).

Figure 2: Sagital (A) and coronal (B) MRI that shows a heterogeneous mass of the left frontal calvarium with erosion of inner and outer table of the skull and (C) roof of the orbit.

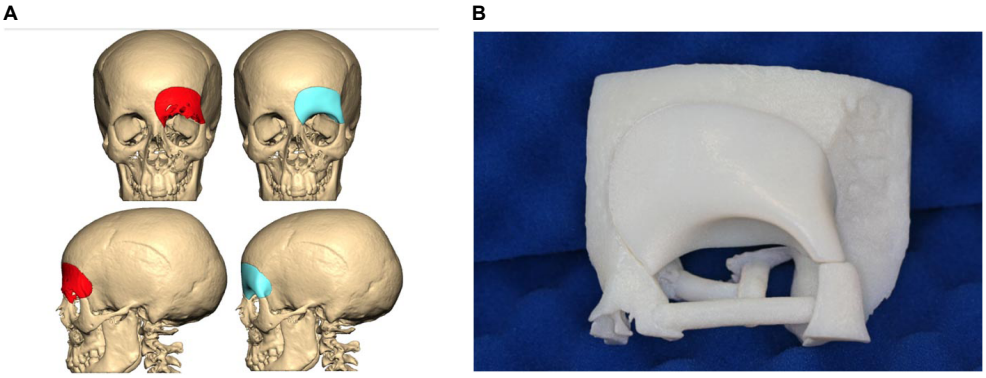

Figure 3: Planning of the resection (A) and implant design (B) sent by the manufacturer for approval.

ISSN 2377-8407 Open Journal http://dx.doi.org/10.17140/SROJ-3-117

A pre-operative high-resolution 3-D CT scan was first obtained from axial images. The images (DICOM format) were sent by CD to the manufacturer. An accurate delineation of the lesion was performed on the software, and based in our measurements, a PEEK prosthesis was manufactured. Implant models were sent to the surgeon for review, mark up and/or approval. The resulting implant had an accuracy to within 0.5 mm.

Surgery was performed *via* a coronal approach. A cranio-orbitotomy allowed to completely excise the large, necrotic, heterogeneous mass. As planned, we performed primary reconstruction of the fronto-orbital defect with a custom-made PEEK prostheis, that was fixed with titanium plates and screws (Figures 4 and 5).

Histopathologic examination demonstrated groups of osteoclast type multinucleated giant cells in a well vascularized, cellular fibrous stroma. There was hemorrhage and cluster of hemosiderin laden macrophages. Reactive woven bone, which displayed osteoblastic activity, was seen in some áreas (Figure 6). Based on the thorough diagnostic work-up including medical history, clinical manifestations, radiographic findings and consecutive routine laboratory findings, the patient was diagnosed as having hyperparathyroidism with brown tumors of facial bones as a result of long-standing renal disease.

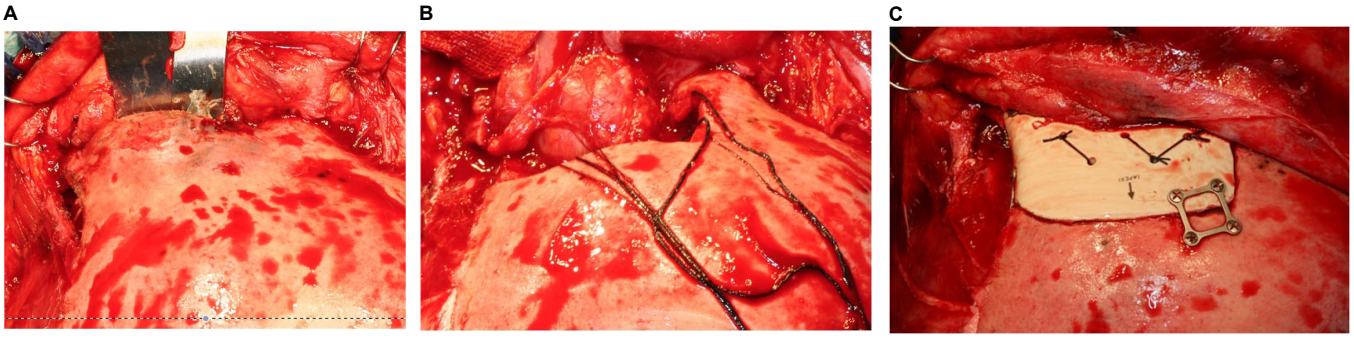

Figure 4: Intraoperative view showing the brown tumor (A), resection (B) and PEEK patient specific implant (PSI) perfectly fitting the bony defect (4C).

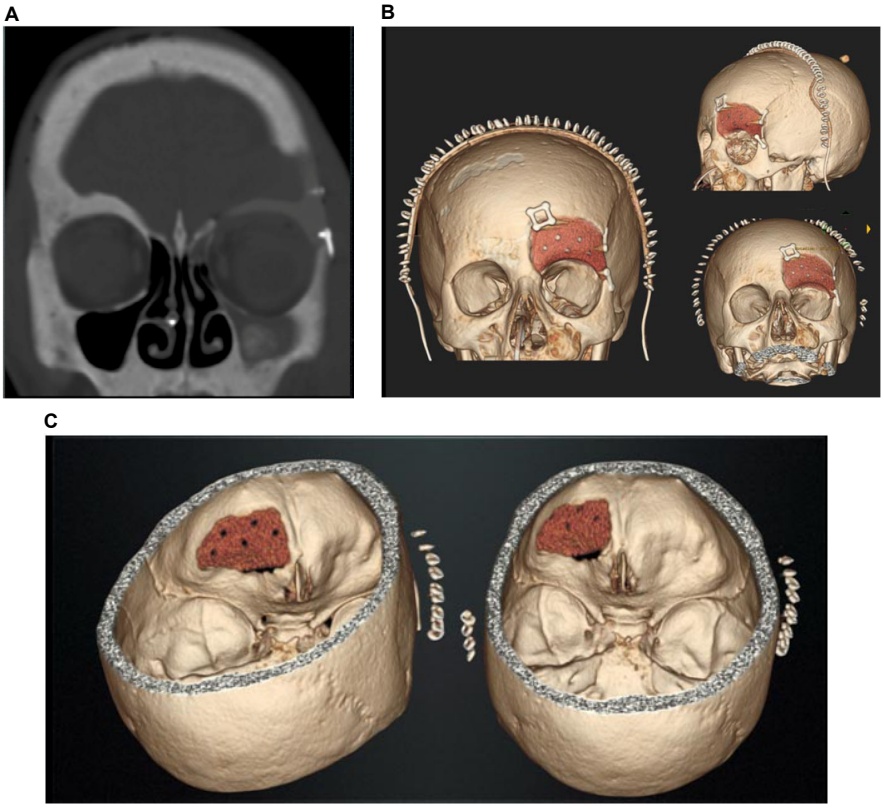

Figure 5: Immediate post-operative CT scan (A) and tridimensional reconstruction of the prosthesis (B and C).

ISSN 2377-8407 Open Journal http://dx.doi.org/10.17140/SROJ-3-117

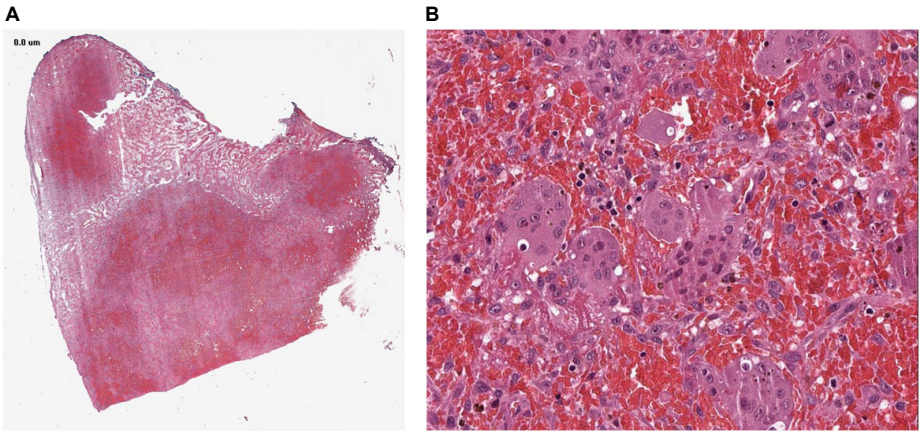

Figure 6: Histopathologic examination revealed a tumor composed of a uniform distribution of multinucleated giant cells in a background of oval to short-spindled stromal cells. These findings were consistent with a giant cell tumor and, in the setting of secondary HPT, the diagnosis of Brown tumor was made. (Figure 6A: H&E x1, Figure 6B: H&E x 200)

Figure 7: Post-operative image, 2 years after surgery, with good cosmetic and functional results.

Two years later, there was no recurrence of the brown tumor, exophthalmos correction and orbital contour symmetry (Figure 7).

DISCUSSION

Brown tumor or osteoclastomas are histologically benign focal lytic bone tumors caused by primary or secondary hyperparathyroidism.[18] They are called brown tumors due to the high hemosiderin level of localized accumulation of osteoclasts, vascularity and hemorrhage, that gives characteristic brown color.[19]

These tumors arise secondary to both primary and secondary hyperparathyroidism. They have been reported to ocurr in 4,5% of patients with primary hyperparathyroidism and 1,5 to 1,7% of those with secondary disease.[20] Secondary HPT is an adaptive response to chronic kidney disease (CKD) as a result of a disruption in serum phosphorus, calcium, and vitamin D homeostasis. Chronic renal disease with secondary retention of phosphates leads to hyperphosphatemia. Deficient 1,25 (OH) vitamin D3 related with renal failure and the resulting hypocalcemia induces to secondary hyperparathyroidism.[21-23] The increase of secretion of parathyroid hormone stimulates the osteoclastic activity with cortical thinning, subperiosteal resorption, bone cysts, and rarely, brown tumors. These tumors represent a reparative cellular process rather than a true neoplasia.[21]

The reported prevalence of brown tumor is 0.1%.[24] They usually affect young people, particularly females. The ribs, clavicle, pelvic girdle, hand, and mandible are their preferred location. The most important complications of this neoformation are related to its position and size and the possible effects on nearby structures.[22] Only few cases have been reported in the fronto-orbital region.[9-17] When the orbit is affected, the presenting symptoms include a palpable mass, pain, proptosis, diplopia, impaired extrinsic ocular motility or decreased visual acuity.

Diagnosis of BTs depends on clinical, biochemical, radiological, and pathological factors.[25] These tumors do not have specific imaging characteristics; sarcomas as well as giant cell reparative granulomas, langerhans cell histiocytosis, aneurysmal bone cysts, metastases, multiple myeloma and non-ossifying fibromas are the other lesions that should be kept in mind as the differential diagnosis.[25-27]

Histologically there is no difference between a brown tumor and a central giant cell granuloma. They contain a mixed population of multinuclear giant cells, mononuclear cells, and osteoblasts. There is high nuclear activity without nuclear

ISSN 2377-8407 Open Journal http://dx.doi.org/10.17140/SROJ-3-117

atypia. Extravasated red blood cells (RBC), areas of hemorrhage and hemosiderin-loaded macrophages usually appear.[28]

The treatment is initially based on the correction of hyperparathyroidism, which usually leads to tumor regression. Surgical excision of the diseased parathyroid gland to control parathyroid hormone (PTH) is the first choice of treatment for a brown tumor because the normalization of parathyroid function and should lead to a reduction in size or disappearance of the tumor.[29]

However, persistent disease is defined and accepted by the authors as the reappearance of typical symptoms, laboratory abnormalities and radiological signs.[30] Surgical resection is indicated in cases of encroachment on neural structures, and when the mass continues for more than 6 months or even grows despite adequate metabolic control.[10,20] In this case, the patient returned with an enlargement of the fronto-orbital lesion 6 months after parathyroidectomy.

Bony lesions in the fronto-orbital region often require extensive bone resections. Reconstructive cranioplasty of such defects remains a challenge for craniofacial surgeons and neurosurgeons. The anatomical complexity of this area requires restoration of the forehead and orbital walls with perfect symmetry to provide good functional and aesthetic results.

Several techniques for fronto-orbital reconstruction in this setting have been described. Autologous bone graft is the standard technique for craniofacial reconstruction in many settings. Donor site morbidity and increased operative time must be the considerations in this approach, and the rigidity of this material may increase the technical challenges of creating a conformational reconstruction of the bony orbital skeleton.[31] Due in part to these limitations, some surgeons have advocated orbital reconstruction with the use of preoperative conformation of biomaterials.[32]

In our case, a 3D CT-scan reconstruction andvirtual surgery allowed planning of the appropriate resection, and helped design the implant. Consequently, an optimal custom-made implant could be used immediately following the surgical resection. We choose to use PEEK biomaterial for this type of craniofacial reconstruction because of numerous advantages: excellent mechanical and chemical properties, biocompatibility and radiographic translucency.[33] Moreover, thin parts can be manufactured on the implant to reconstruct orbital walls for example, and PEEK can be drilled for rigid plate fixation to the maxillofacial skeleton. These implants have the advantage of being preoperatively tailored to the exact size of the cranial defect, thus allowing a shortening of the operative time as well as the amount of the intraoperative modifications, hence guaranteeing post-operative stability and incomparable cosmetic results.[34] In our case, PEEK implant allowed one-step reconstruction of the fronto-orbital region achieving symmetry and functional results, reducing operative time and avoiding donor site morbidity.

CONFLICTS OF INTEREST

The authors declare that they have no conflicts of interest.

CONSENT

The patient has provided written permission for publication of the case details.

REFERENCES

1. Triantallidou K, Zouloumis L, Karakinaris G, et al. Brown tumours of the jaws associated with primary or secondary hyperparathyroidism. A clinical study and review of literature. *Am J Otolaryngol.* 2006; 27(4): 281-286. doi: 10.1016/j.amjoto.2005.11.004

2. Lessa MM, Sakae FA, Tsuji RK, et al. Brown tumor of the facial bones: Case report and literature review. *Ear Nose hroat J.* 2005; 84: 432. Web site. http://www.entjournal.com/sites/ent-journal.com/files/archive/www.entjournal.com/Media/PublicationsArticle/LESSA-07-05.pdf. Accessed July 19, 2016

3. Martinez-Gavidia EM, Bagan JV, Millan-Masanet MA, et al. Highly aggressive brown tumour of the maxilla as first manifestation of primary hyperparathyroidism. *Int J Oral Maxillofac Surg*. 2000; 29: 447-449. doi: 10.1016/S0901-5027(00)80079-X

4. Kar DK, Gupta SK, Agarwal A, et al. Brown tumor of the palate and mandible in association with primary hyperparathyroidism. *J Oral Maxillofac Surg*. 2001; 59: 1352-1354. doi: 10.1053/joms.2001.27533

5. Yamazaki H, Ota Y, Aoki T, et al. Brown tumor ofthe maxilla and mandible: Progressive mandibular brown tumor after removal of parathyroid adenoma. *J Oral Maxillofac Surg*. 2003; 61: 719-722. doi: 10.1053/joms.2003.50142

6. Corbetta S, Rossi D, D'Orto O, et al. Brown jaw tumor: Today's unusual presentation of primary hyperparathyroidism. *J Endocrinol Invest.* 2003; 26: 675. doi: 10.1007/BF03347028

7. Daniel JS. Primary hyperparathyroidism presenting as apalatal brown tumor. *Oral Surg Oral Med Oral Pathol Oral Radiol Endod.* 2004; 98(4): 409-413. doi: 10.1016/j.tripleo.2004.01.015

8. Suarez-Cunqueiro MM, Schoen R, Kersten A, Klish J, Schmelzeinsen R. Brown tumor of the mandible as first manifestation of atypical parathyroid adenoma. *J Oral Maxillofac Surg.* 2004; 62: 1024-1028. doi: 10.1016/j.joms.2004.02.011

9. Park K, Mannor GE, Wolfley DE. Preoperative embolization of an orbital brown tumor. *Am J Ofthalmol.* 1994; 117(5): 679-680. doi: 10.1016/S0002-9394(14)70086-8

10. Gonzalez-Martínez E, Santamarta-Gómez D, Varela-Rois P, et al. Brown tumor of the orbital roof as an initial and isolated manifestation of secondary hyperparathyroidism. *Orbit.* 2010; 29(5): 278-280. doi: 10.3109/01676830.2010.501947

11. Levine MR, Chu A, Abdul-Karim FW. Brown tumor and secondary hyperparathyroidism. *Arch Ophthalmol.* 1991; 109(6): 847-849. doi: 10.1001/archopht.1991.01080060111036

12. Parrish CM, O'Day DM. Brown tumor of the orbit: Case report and review of the literature. *Arch Ophthalmol*. 1986; 104(8): 1199-1202. doi: 10.1001/archopht.1986.01050200105061

13. Zwick OM, Vagefi MR, Cockerham KP, et al. Brown tumor of secondary hyperparathyroidism involving the superior orbit and frontal calvarium. *Ophthal Plast Reconstr Surg.* 2006; 22(4): 304. doi: 10.1097/01.iop.0000225744.19613.3d

14. Naiman J, Green WR, d'Heurle D, et al. Brown tumor of the orbit associated with primary hyperparathyroidism. *Am J Ophthalmol.* 1980; 90(4): 565-571. Web site. http://europepmc.org/abstract/med/7424756. Accessed July 19, 2016

15. Holzer NJ, Croft CB, Walsh JB, et al. Brown tumor of the orbit. *JAMA*. 1977; 238(16): 1758-1759. doi: 10.1001/jama.1977.03280170052029

16. Zwick OM, Vagefi MR, Cockerham KP, et al. Brown tumor of secondary hyperparathyroidism involving the superior orbit and frontal calvarium. *Ophthal Plast Reconstr Surg*. 2006; 22(4): 304-306. doi: 10.1097/01.iop.0000225744.19613.3d

17. Ribeiro Monteiro ML. Multiple brown tumors of the orbital walls: Case report. *Arq Bras Oftalmol.* 2009; 72 (1): 116-118. doi: 10.1590/S0004-27492009000100025

18. Vandenbussche E, Schmider L, Mutschler C, Man M, Jacquot C, Augereau B. Brown tumor of the spine and progressive paraplegia in a hemodialysis patient. *Spine.* 2004; 29(12): E251-E255. doi: 10.1097/01.BRS.0000127187.58944.FA

19. Noman Zaheer S, Byrne ST, Poonnoose SI, Vrodos NJ. Brown tumour of the spine in a renal transplant patient. *J Clin Neurosci*. 2009; 16(9): 1230-1232. doi: 10.1016/j.jocn.2008.11.009

20. Kanaan I, Ahmed M, Rifai A, Alwatban J. Sphenoid sinus Brown tumor of secondary hyperparathyroidism: Case report. *Neurosurgery.* 1998; 42(6): 1374-1377. Web site. http://journals.lww.com/neurosurgery/pages/articleviewer.aspx?year=1998&issue=06000&article=00113&type=abstract. Accessed July 19, 2016

21. Duran C, Ersoy C, Bolva N. Brown tumors of the maxillary sinus and patella in a patient with primary hyperparathyroidism. *Endocrinologist*. 2005; 15(6): 351-354. doi: 10.1097/01.ten.0000188456.73682.a8

22. Di Daniele N, Condò S, Ferrannini M, et al. Brown tumour in a patient with secondary hyperparathyroidism resistant to medical therapy: Case report on successful treatment after subtotal parathyroidectomy. *Int J Endocrinol*. 2009; 2009: 827652. doi: 10.1155/2009/827652

23. Monteiro ML. Multiple brown tumors of the orbital walls: Case report. *Arq Bras Oftalmol.* 2009; 72(1): 116-118. doi: 10.1590/S0004-27492009000100025

24. Keyser JS, Postma GN. Brown tumor of the mandible. *AM J Otolaryngol*. 1996; 17(6): 407-410. doi: 10.1016/S0196-0709(96)90075-7

25. Grégoire C, Soussan M, Dumuis ML, et al. Contribution of multimodality imaging for positive and aetiological diagnosis of multiple brown tumours. *Ann Endocrinol.* 2012; 73(1): 43-50. doi: 10.1016/j.ando.2011.10.002

26. Pavlovic S, Valyi-Nagy T, Profirovic J, David O. Fine-needle aspiration of brown tumor of bone: Cytologic features with radiologic and histologic correlation. *Diagn Cytopathol.* 2009; 37(2): 136-139. doi: 10.1002/dc.20974

27. Mateo L, Massuet A, Solà M, et al. Brown tumor of the cervical spine: A case report and review of the literature. *Clin Rheumatol.* 2011; 30(3): 419-424. doi: 10.1007/s10067-010-1608-y

28. de Ávila ED, de Molon RS, Cabrini Gabrielli MA, et al. Unusually rapid growth of brown tumour in the mandible after parathyroidectomy associated with the presence of a super numerary parathyroid gland. *J Cranio-Maxillo-Fac Surg*. 2012; 40: 19.

29. Pinto LP, Cherubinin K, Salum FG, Yurgel LS, de Figueiredo MA. Highly aggressive brown tumour in the jaw associated with tertiary hyperparathyroidism. *Pediatr Dent.* 2006; 28(6): 543-546. Web site. http://www.ingentaconnect.com/content/aapd/pd/2006/00000028/00000006/art00011?token=004e155756b705c5f3b3b474673487734447b516e755f6c4f582a2f4876753375686f49dd61efc. Accessed July 19, 2016

30. Hindié E, Fregonara PZ, Just PA, et al. Parathyroid scintigraphy findings in chronic kidney disease patients with recurrent hyperparathyroidism. *Eur J Nucl Med Mol Imaging.* 2010; 37(3): 623. doi: 10.1007/s00259-009-1313-8

31. Chambless LB, Mawn LA, Forbes JA, et al. Porous polyethylene implant reconstruction of the orbit after resection of spheno-orbital meningiomas: A novel technique. *J CranioMaxilloFac Surg.* 2012; 40(1): e28-e32. doi: 10.1016/j.jcms.2011.01.016

32. Jalbert F, Lauwers F. Reconstruction de la voûte crânienne. *Ch Plast Rec*. 2009; 57.

ISSN 2377-8407 Open Journal http://dx.doi.org/10.17140/SROJ-3-117

33. Nieminen T, Kallela I, Wuolijoki E, Kainulainen H, Hiidenheimo I, Rantala I. Amorphous and crystalline polyetheretherketone: Mechanical properties and tissue reactions during a 3-year follow-up. *J Biomed Mater Res*. 2008; 84(2): 377-383. doi: 10.1002/jbm.a.31310

34. Scolozzi P, Martinez A, Jaques B. Complex orbito-fronto-temporal reconstruction using computer-designed PEEK implant. *J Craniofac Surg*. 2007; 18(1): 224-228. doi: 10.1097/01.scs.0000249359.56417.7e

SURGICAL RESEARCH

Openventio PUBLISHERS

ISSN 2377-8407 Open Journal http://dx.doi.org/10.17140/SROJ-3-118

Mini Review

*Corresponding author
Lisa Beth Spiryda, MD, PhD
Associate Professor
Department of Obstetrics and Gynecology
University of Florida, College of Medicine
PO BOX 100294 Gainesville
FL 32610, USA
Tel. (352)273-7660
E-mail: spirlb@ufl.edu

Volume 3 : Issue 1
Article Ref. #: 1000SROJ3118

Article History
Received: August 31st, 2016
Accepted: September 8th, 2016
Published: September 8th, 2016

Citation
Lipman M, Spiryda LB. The opportunistic salpingectomy in reducing ovarian cancer risk: Do the potential benefits outweigh complications? *Surg Res Open J*. 2016; 3(1): 20-23. doi: 10.17140/SROJ-3-118

The Opportunistic Salpingectomy in Reducing Ovarian Cancer Risk: Do the Potential Benefits Outweigh Complications?

Malorie Lipman, BS; Lisa Beth Spiryda, MD, PhD*

Department of Obstetrics and Gynecology, University of Florida, College of Medicine
PO BOX 100294 Gainesville, FL 32610, USA

ABSTRACT

A 33-year-old women with 3 children who has completed child bearing presents to your office for permanent sterilization *via* a laparoscopic approach. She has recently heard through the internet that removal of the fallopian tubes completely may decrease her ovarian cancer risk more than a tubal ligation with placement of clips or cauterization. She has no family history of gynecologic malignancies but is now curious about preventative measures for ovarian cancer that can decrease her risk. How do you counsel this patient?

KEYWORDS: Cancer; Fallopian tubes; Gynecologic malignancies; Tumors.

ABBREVIATIONS: BRCA 1 or BRCA 2: BReast CAncer genes 1 or 2; ACOG: American College of Obstetricians and Gynecologists; EOC: Epithelial Ovarian Cancer; PPC: Primary Peritoneal Cancer; BSO: Bilateral Salpingo-Oophorectomy; BTIs: Biliary Tract Infections; BS: Bilateral Salpingectomy; RCT: Randomized Control Trials.

INTRODUCTION

Ovarian cancer is the leading cause of gynecologic malignancies in the United States and the 5th most common cause of cancer deaths in women.[1,2] Screening methods have shown no mortality benefits, and symptoms are non-specific leading to delays in diagnosis. The most common form of ovarian cancer is epithelial carcinoma, with stromal/sex cord tumors and germ cell tumors much less common. The most common types of epithelial ovarian cancer, in decreasing order, are serous (50%), mucinous (25%), endometrioid (15%), clear cell, and transitional or Brenner tumor. The diagnosis of ovarian cancer is often in late stages, leading to a five-year survival rate of less than 50%.[2] While the risk of ovarian cancer in genetically predisposed patients with (BReast CAncer genes 1 or 2) BRCA 1 or BRCA 2 mutations ranges from 20-50%, the risk for the general population remains at less than 2%.[2] Many genetically predisposed women may decide to undergo prophylactic surgeries to decrease their risk of developing ovarian cancer and face the consequence of surgical premature ovarian failure.

The fallopian tubes, specifically the fimbriae, have been suggested as possible originating sites of epithelial ovarian cancers.[3] Historically, cancer of the fallopian tubes had been the least common gynecologic malignancy (0.3%). Zweemer et al's[4] findings suggested an increased incidence of fallopian tube cancer in patients harboring a BRCA 1 mutation and suggested that carriers undergoing prophylactic oophorectomy may benefit from considering salpingectomy as well. Peritoneal washings performed at the time of surgery have found unsuspected fallopian tube carcinoma.[5,6] These early diagnoses made it possible to identify fallopian tube carcinoma before significant spread to the ovary, which makes differentiation more difficult and likely leads to under-reporting of primary tubal carcinoma. Additionally, fallopian tube sectioning at the time of salpingo-oophorectomy for serous carcinoma has shown tubal involve-

ISSN 2377-8407 Open Journal http://dx.doi.org/10.17140/SROJ-3-118

ment in a significant portion, particularly the distal tube and fimbriae.[7] Bilateral tubal interruptions have been shown to have a negative association with epithelial ovarian cancer. Several possible mechanisms have been proposed, with the most common being an interruption in retrograde migration of epithelial tissue from the uterus to the ovaries.[8-10]

These recent findings that a proportion of ovarian carcinomas may originate in the fallopian tubes have led to the consideration of excisional sterilization techniques (salpingectomy), rather than non-excisional (clips, cauterization), to further decrease this risk. Also consideration for concurrent salpingectomy during a hysterectomy for benign reasons (e. g., menorrhagia, uterine leiomyomas)

Proposals for prophylactic surgeries were first made in BRCA positive patients. Surgeries included bilateral salpingo-oophorectomy as well as bilateral salpingectomy and delayed oophorectomy. There is less literature on the benefits of these prophylactic surgeries in BRCA negative patients.

This review will present the current literature on salpingectomy as a means of risk reduction of epithelial ovarian carcinoma including the potential drawbacks, the benefits, and the current physician adoption of salpingectomy as a means of sterilization.

POTENTIAL BENEFITS

The American College of Obstetricians and Gynecologists (ACOG) released their committee opinion in January 2015 suggesting salpingectomy as an option to be discussed with patients for sterilization and as having potential for ovarian cancer prevention. This recommendation is also extended to women undergoing hysterectomy procedures.

There have been several studies examining the absolute decrease risk of ovarian cancers in healthy women undergoing tubal ligations procedures including non-excisional procedures; tubal ligation alone appears to decrease risk of ovarian cancers. Sieh et al[9] pooled primary data from 13 population based case control studies in various countries including the US, Germany, Denmark, Australia, and Canada. These included 13,904 controls, 7942 invasive ovarian cancer cases, and 2215 borderline ovarian tumors and assessed whether the women had surgical history of a non-excisional (cauterization, clips) tubal ligation. They found a 29% reduced risk of invasive ovarian cancer overall after accounting for numerous confounders. Reduced risks were consistently found for every site and across 4 histologic subtypes: endometrioid, clear cell, mucinous and serous high grade ovarian. This study did not include excisional tubal procedures.

Madsen et al[11] performed a case control study of the entire female Danish population that included all women in Denmark diagnosed with epithelial ovarian carcinoma or borderline carcinoma between 1982 and 2011. Tubal ligation alone was associated with a statistically significant decreased risk of ovarian carcinoma, highest for endometrioid tumors (odds ratio (OR)=0.87; 95% confidence interval (CI) 0.78-0.98). Bilateral salpingectomy was associated with an overall 42% decreased risk of epithelial ovarian carcinoma (OR=0.58; 95% CI 0.36-0.95). Benefits of this study included histologic verification of tissue, use of national registry to eliminate recall and selection bias, and population size (13,241 cases with epithelial ovarian cancer (EOC) and 3,605 with borderline ovarian tumors matched with randomly selected 15 female population controls).

Similar were found in a nested case control study using Rochester Epidemiology Project data between 1966 and 2009.[12] One hundred and ninety-four cases of serous EOC and primary peritoneal cancer (PPC) were matched with 388 controls. Any type of tubal sterilization procedure conferred a 46% decrease risk of serous EOC and PPC (OR, 0.54; 95% CI 0.28-1.04; p=0.07). There was a 64% risk reduction among excisional techniques compared to no sterilization and non-excisional techniques combined, however once other factors such as OCP use, pregnancy, and live births were adjusted for (as these were more common in non-excisional techniques) this decreased to 23% risk reduction, which was no longer statistically significant. Limitations encountered were missing operative reports and low statistical power due to a small amount of cases.

Falconer et al[13] in 2015 utilized a large population based cohort study from 1973-2009 on the general population in Sweden with the primary outcome of ovarian and tubal cancer, excluding borderline carcinomas as these have been shown as stated above to not be associated with bilateral tubal interruption (BTIs). Researchers compared outcomes in women who had undergone hysterectomy (98,026), hysterectomy+bilateral salpingo-oophorectomy (BSO) (37,348), salpingectomy (34,433), and non-excisional sterilization (81,658). Mean age at entry was 35.9 years and mean follow-up was 23.1 years. Women were excluded if they had had any gynecologic surgical procedure prior to entering the cohort. Three-thousand and fifty-one women were identified as having two-sided salpingectomies and 19,552 as having one-sided salpingectomies. Both unilateral and bilateral salpingectomies were associated with statistically significant risk reductions, however bilateral salpingectomy was associated with an additional 50% decrease compared with a unilateral procedure. Number needed to treat for bilateral salpingectomy group was about 300 women, which is expected for a cancer with lower incidence. Statistically significant results were only observed at least 10 years out from surgery in all groups except for the hysterectomy group. This suggests a true association as opposed to a "healthy screenee effect".

Level one evidence with randomized control trials have not been performed as of this time, there is a consistent risk reduction for ovarian cancers after bilateral salpingectomy (performed for sterilization and concurrent with a hysterectomy) in cohort studies and retrospective analyses.

ISSN 2377-8407 Open Journal http://dx.doi.org/10.17140/SROJ-3-118

POTENTIAL HARMS

Several potential complications have been hypothesized including increased length of surgery and complication rates, increased length of hospitalization and readmission, necessity of blood transfusion, and increased cost.

Early studies have brought to light the potential complications that salpingectomy may have on patients, both during and after the procedure. The large retrospective cohort study by McAlpine et al[14] brought to light several peri-operative differences in procedures with and without salpingectomy. The mean difference in operating time was found to be statistically significantly longer among hysterectomies with bilateral salpingectomy when compared to hysterectomy alone (16 minutes; $p<.001$). Patients who underwent hysterectomy alone were found to actually have slightly longer length of stay compared to patients who underwent hysterectomy+bilateral salpingectomy (2.52 days *vs.* 2.37 days; $p=.010$). Hospital readmission and need for blood transfusion was not significantly different between hysterectomy alone group and hysterectomy+salpingectomy.

For patients who underwent salpingectomy for sterilization compared with tubal ligation, mean OR time was increased significantly by 10.2 minutes ($p<.001$).[14] There were no significant differences found for length of stay, readmission, or blood transfusion.

Many of the women in the general population that may undergo prophylactic salpingectomy are premenopausal, therefore, ovarian function post-procedure is an important factor to take into consideration. Preliminary studies have found no significant differences in ovarian function by measuring changes in anti-mullerian hormone levels, follicle stimulating hormone levels, change in antral follicle number, change in mean ovarian diameter, and change in peak systolic velocity.[15,16] Salpingectomy did not significantly affect ovarian function based on the above measurements.

Another concern about performing salpingectomy as sterilization or as part of a concurrent procedure with hysterectomy has also been cost. Cost analysis was assessed using a Monte Carlo simulation model comparing opportunistic salpingectomies to non-excisional tubal ligations, as well as comparing hysterectomies alone, with combined bilateral salpingectomy (BS) or combined bilateral salpingo-oophorectomy (BSO).[17] When comparing salpingectomy to non-excisional tubal ligation, it was found to be cost effective for reducing the risk of ovarian carcinoma so long as the cost of salpingectomy does not exceed that for a tubal ligation by more than $1000. The simulator found that taking into account all costs, hysterectomy combined with bilateral salpingectomy was more cost effective than either hysterectomy alone and hysterectomy+BSO. Compared with hysterectomy+BSO, hysterectomy+BS was less effective at preventing ovarian cancer as would be expected, but conferred more risk reduction than hysterectomy alone. Most importantly, bilateral salpingectomy did not increase the risk of other cancers (lung, colorectal) and cardiovascular disease as a BSO. The number needed to treat with an opportunistic salpingectomy to prevent one case of ovarian cancer was 273-366. The high number needed to treat offsets the apparent gain in life expectancy for women affected by ovarian carcinoma that could have been prevented by an opportunistic salpingectomy.

Although surgical time appears to be increased in these retrospective studies, complication rates appear to be low for salpingectomy without increasing overall costs.

CONCLUSIONS

The recent findings of the benefits along with the low risk profile associated with salpingectomies have led to a steady increase in salpingectomies. In addition to evaluating risks and complications of the procedure, McAlpine et al[11] also evaluated procedural uptake after a 2010 educational initiative in British Columbia. The most striking evidence was the statistically significant increase in salpingectomy specifically for sterilization. Combined hysterectomy+salpingectomy also significantly increased.

Randomized control trials (RCT) are still lacking, especially among women with general population risk. Findings thus far have found repeated associations between tubal procedures and serous, endometrioid, and clear cell epithelial carcinomas, and very few potential risks have been associated with salpingectomy, including increased surgical risks and decreased ovarian reserve.

It is well known that ovarian cancer is the leading cause of gynecologic malignancy death, the fifth leading cause of cancer death in women, and that screening programs have had little success. The current literature, although limited, has shown that non-excisional tubal sterilization procedures are associated with decreased ovarian cancer rates, with excisional procedures reducing the risk further, and these results have been replicated. Although level-one evidence is lacking and ACOG is unable to make an absolute recommendation for women with general population risk, shared patient-physician decision-making is most acceptable. The potential benefits are promising, and risks appear to be low; therefore bilateral salpingectomy can be recommended and encouraged in low-risk women presenting for permanent sterilization as well as those undergoing hysterectomy for benign reasons.

CONFLICTS OF INTEREST

The authors declare that they have no conflicts of interest.

REFERENCES

1. Hoffman B, Griffith W, Moschos E, et al. *Williams Gynecology.* NY, USA: McGraw-Hill; 2012.

2. Kantarjian HM, Wolf RA. *The MD Anderson Manual of Medical Oncology*. NY, USA: McGraw-Hill; 2016.

3. Crum CP, Drapkin R, Kindelberger D, Medeiros F, Miron A, Lee Y. Lessons from BRCA: The tubal fimbria emerges as an origin for pelvic serous cancer. *Clin Med Res*. 2007; 5(1): 35-44. doi: 10.3121/cmr.2007.702

4. Zweemer RP, van Diest PJ, Verheijen RH, et al. Molecular evidence linking primary cancer of the fallopian tube to BRCA1 germline mutations. *Gynecol Oncol.* 2000; 76(1): 45-50. doi: 10.1006/gyno.1999.5623

5. Agoff SN, Mendelin JE, Grieco VS, Garcia R. Unexpected gynecologic neoplasms in patients with proven or suspected BRCA-1 or -2 mutations: Implications for gross examination, cytology, and clinical follow-up. *Am J Surg Pathol*. 2002; 26(2): 171-178. Web site. http://journals.lww.com/ajsp/Abstract/2002/02000/Unexpected_Gynecologic_Neoplasms_in_Patients_With.3.aspx. Accessed August 30, 2016

6. Colgan TJ, Boerner SL, Murphy J, Cole DE, Narod S, Rosen B. Peritoneal lavage cytology: An assessment of its value during prophylactic oophorectomy. *Gynecol Oncol.* 2002. 85(3): 397-403. doi: 10.1006/gyno.2002.6638

7. Kindelberger DW, Lee Y, Miron A, et al. Intraepithelial carcinoma of the fimbria and pelvic serous carcinoma: Evidence for a causal relationship. *Am J Surg Pathol*. 2007; 31(2): 161-169. doi: 10.1097/01.pas.0000213335.40358.47

8. Ness RB, Cottreau C. Possible role of ovarian epithelial inflammation in ovarian cancer. *J Natl Cancer Inst.* 1999; 91(17): 1459-1467. doi: 10.1093/jnci/91.17.1459

9. Sieh W, Salvador S, McGuire V, et al. Tubal ligation and risk of ovarian cancer subtypes: A pooled analysis of case-control studies. *Int J Epidemiol.* 2013. 42(2): 579-589. doi: 10.1093/ije/dyt042

10. Woodruf JD. The pathogenesis of ovarian neoplasia. *Johns Hopkins Med J.* 1979. 144(4): 117-120. Web site. http://europepmc.org/abstract/med/374819. Accessed August 30, 2016

11. Madsen C, Baandrup L, Dehlendorff C, Kjaer SK. Tubal ligation and salpingectomy and the risk of epithelial ovarian cancer and borderline ovarian tumors: A nationwide case-control study. *Acta Obstet Gynecol Scand.* 2015; 94(1): 86-94. doi: 10.1111/aogs.12516

12. Lessard-Anderson CR, Handlogten KS, Molitor RJ, et al. Effect of tubal sterilization technique on risk of serous epithelial ovarian and primary peritoneal carcinoma. *Gynecol Oncol*. 2014; 135(3): 423-427. doi: 10.1016/j.ygyno.2014.10.005

13. Falconer H, Lin Y, Gronberg H, Altman D. Ovarian cancer risk after salpingectomy: A nationwide population-based study. *J Natl Cancer Inst.* 2015; 107(2). doi: 10.1093/jnci/dju410

14. McAlpine JN, Hanley GE, Woo MM, et al. Opportunistic salpingectomy: Uptake, risks, and complications of a regional initiative for ovarian cancer prevention. *Am J Obstet Gynecol*. 2014; 210(5): 471 e1-e11. doi: 10.1016/j.ajog.2014.01.003

15. Findley AD, Siedhoff MT, Hobbs KA, et al. Short-term effects of salpingectomy during laparoscopic hysterectomy on ovarian reserve: A pilot randomized controlled trial. *Fertil Steril.* 2013. 100(6): 1704-1708. doi: 10.1016/j.fertnstert.2013.07.1997

16. Morelli M, Venturella R, Mocciaro R, et al. Prophylactic salpingectomy in premenopausal low-risk women for ovarian cancer: Primum non nocere. *Gynecol Oncol*. 2013; 129(3): 448-451. doi: 10.1016/j.ygyno.2013.03.023

17. Kwon JS, McAlpine JN, Hanley GE, et al. Costs and benefits of opportunistic salpingectomy as an ovarian cancer prevention strategy. *Obstet Gynecol.* 2015. 125(2): 338-345. doi: 10.1097/AOG.0000000000000630