

Systematic Review

***Corresponding author**

Omar Ramadan, PhD

ENT Registrar
Independent Researcher
Paterson, NJ 07533, USA
Tel. +1 973 563 9283

E-mail: omarram982@hotmail.com

Volume 3 : Issue 1

Article Ref. #: 1000OTLOJ3134

Article History

Received: November 18th, 2016

Accepted: December 28th, 2016

Published: December 28th, 2016

Citation

Ramadan O. Radiation-induced parotid mucoepidermoid carcinoma: A systematic review. *Otolaryngol Open J.* 2016; 3(1): 9-15. doi: [10.17140/OTLOJ-3-134](https://doi.org/10.17140/OTLOJ-3-134)

Copyright

©2016 Ramadan O. This is an open access article distributed under the Creative Commons Attribution 4.0 International License (CC BY 4.0), which permits unrestricted use, distribution, and reproduction in any medium, provided the original work is properly cited.

Radiation-Induced Parotid Mucoepidermoid Carcinoma: A Systematic Review

Omar Ramadan, PhD*

Independent Researcher, Paterson, NJ 07533, USA

ABSTRACT

Background: Mucoepidermoid Carcinoma (MEC) of the parotid gland has been reported in patients who have been previously exposed to radiation. The purpose of this article is to review the literature examining radiation-induced parotid gland MEC.

Procedure: A PubMed search of related articles in English was performed using a combination of the following keywords: “radiation induced parotid tumors,” “radiation induced salivary gland tumors,” “radiation induced parotid MEC,” “radiation induced salivary gland MEC.”

Results: The search results indicated 18 related articles describing the condition of 40 patients who have been previously exposed to radiation and subsequently developed parotid MEC. According to pre-existing studies, acute lymphoblastic leukemia (ALL) was a common observation among the patients following the initial diagnosis. The patients were divided into two groups on the basis of the treatment they received which included patients subjected to radiotherapy (RT) alone (n=13) and patients subjected to both radiotherapy and chemotherapy (n=27). The recorded latent time for secondary MEC development was significantly reduced in the chemoradiotherapy group of patients relative to the group undergoing radiotherapy alone. The overall survival rate for patients recorded over a period of 2 and 5 years was recorded as 97.4% and 95.4% respectively. The overall locoregional control rates recorded over a period of 2 years and 5 years were 97.4% and 93.1% respectively. There was no Significant difference in the recorded survival or locoregional control rates between the groups of patients exposed to radiation alone or a combination of chemotherapy and radiotherapy.

Conclusion: Radiation-induced parotid MEC has an excellent prognosis supporting the survival of over 90% diagnosed patients.

KEY WORDS: Radiation induced parotid tumors; Radiation induced salivary gland tumors; Radiation induced parotid MEC; Radiation induced salivary gland MEC.

ABBREVIATIONS: MEC: Mucoepidermoid Carcinoma; ALL: Acute Lymphoblastic Leukemia; RT: Radiotherapy; LT: Latent time.

INTRODUCTION

Salivary gland tumors are uncommon tumors that represent about 1% of head and neck tumors, only 5% of which occur among children. Among epithelial tumors of the salivary glands, mucoepidermoid carcinoma (MEC) is the most frequently observed histological type of cancer occurring in both adults and children. It is also the most common type of parotid gland malignancies. Parotid gland MEC may be characterized by symptoms such as the formation of a painless mass, facial weakness, referred otalgia, trismus and parenthesis. MEC can occur either as a primary or secondary malignancy. Exposure to radiation has been associated with an increased risk of developing secondary parotid MEC. Multiple cases have been reported about the incidence of secondary MEC in patients exposed to radiotherapy. Long-term evaluation and a high index of suspicion for second cancers are mandatory for all patients had radiotherapy previously. The secondary salivary MEC usually develop years or even decades after treatment of the first neoplasm has been completed. Since the survival of patients with cancer is improving, particularly amongst children, awareness of the spectrum of possible second tumors like parotid gland MEC is of increasing importance. The purpose of our article is to review

the literature investigating the cases of parotid MEC induced by radiation.¹⁻³

MATERIALS AND METHODS

Search Strategy

A systematic review was conducted for all cases of radiation induced Parotid MEC from 1967 to 2016 using the PubMed database.

Search criteria were input as “radiation induced parotid tumors”, “radiation induced salivary gland tumors,” “radiation induced parotid MEC,” and “radiation induced salivary gland MEC.”.

Six hundred seventeen initial articles were obtained. Articles were then filtered to exclude non-human and non-English language research.

Abstracts were first reviewed to search for articles that discussed cases of MEC induced by radiation occurring in the parotid gland and full-text articles were subsequently selected and reviewed for extraction of data. References of the included studies were examined for additional cases.

Selection Criteria and Data Extraction

All English, human studies that reported individual data for radiation induced parotid mucoepidermoid carcinoma were included if they reported diagnosis, treatment, follow-up, and outcome.

Non-human, radiologic, cadaveric, anatomical, and histological studies were excluded, as were sources with insufficient or unextractable data. Articles with unobtainable full text were also excluded.

Outcome measures extracted included: demographic data, radiation dose for primary disease, latent time, primary treatment modality, secondary parotid MEC treatment, follow-up, recurrence, metastasis.

Two-year overall survival and locoregional control were calculated using the Kaplan-Meier method. Differences in the survival rates were assessed by the log-rank test. All *p* values were two sided, and a *p* value <0.05 was adopted as the threshold for significance (Figure 1).

RESULTS

The final PubMed searches using the keywords yielded 18 studies comprising a total of 40 patients which were left for analysis. All 18 studies included individual patient data that was extractable and fit the minimum criteria for inclusion (Table 1).

Patients Characteristics

Our study yielded 40 patients with RT related MEC of parotid gland. The median age during primary diagnosis was 11.9 years (range 0.3-28 years); the male to female ratio was 17/23 (Table 2).

Initial Diagnosis conditions

The most commonly observed results of diagnosis were ALL (n=14), acne and skin disorders (n=6), and Hodgkins lymphoma (n=5). The other results following diagnosis included thyroid papillary tumor (n=3), AML (n=2), NPC (n=2), rhabdomyosarcoma (n=2) and astrocytoma (n=2). There was one recorded case each of CML, medulloblastoma, neuroblastoma, retinoplastoma and recurrent sore throat.

The treatment for initial tumor or similar condition in-

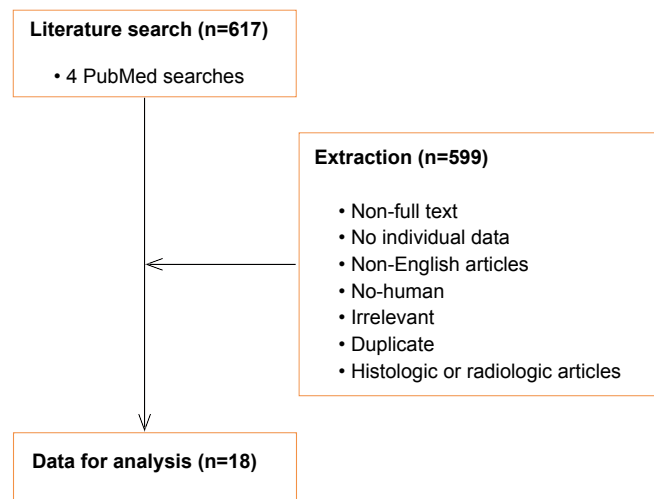


Figure 1: Flowchart of the study selection process.

		Age at RT Exposure	Age At diagnosis	LT	Primary condition	Treatment for Initial condition	Treatment for Secondary MEC	Outcomes	Follow Up	Grade
Beal et al ¹	M	12	28	16	Hodgkin	RT+C 44 Gy	Surgery	NED	86 mo 7 yr	I
	M	17	32	15	Hodgkin	RT+C 30 Gy	Surgery RT	NED	22 mo 2 yr	II
	F	28	34	8	Hodgkin	RT+C 36 Gy	Surgery	NED	22 mo 2 yr	I
	M	15	58	43	Acne	RT Low dose	Surgery	NED	6 mo 1 yr	I
	F	15	79	64	Acne	RT Low dose	Surgery RT	NED	8 mo 1 yr	II
	M	15	21	6	NPC	RT 70 Gy	Surgery	NED	100 mo 8 yr	I
	F	5	50	45	Ringworm	RT Low dose	Surgery RT	NED	28 mo 2 yr	II
Prasannan et al ²	M	22	10	9	ALL	RT+C 18 Gy	Surgery	NED	24 mo 2 yr	I
	F	3	12	9	ALL	RT+C 18 Gy	Surgery	NED	7 yr	I
Whatley et al ⁴	5 M 3 F			29	NPC	RT+C 41	Surgery ND	NED	3 yr alive with distant	III
				11	Rhabdomyosarcoma	RT+C 37	Surgery ND RT	NED	6 yr	III
				13	Astrocytoma	RT 54	Surgery	NED	6 yr	II
				8	ALL	RT+C 24	Surgery RT	NED	6 yr	II
				3	Hodgkins	RT+C 24	Surgery	NED Local recurrence after 3 year reoperated	3 yr	II
				5	CML	RT+C 14	Surgery ND RT	NED	3 yr	II
				9	ALL	RT+C 24	Surgery RT	NED	9 yr	I
				5	ALL	RT+C 18	Surgery	NED	5 yr	I
Rodriguez-cuevas et al ⁵	F	15,5	19	3,5	Thyroid papillary tumor	RT 100 mci radioiodine	Surgery	NED	1 yr	I
Henze et al ⁶	F	20	39	19	Thyroid papillary tumor	RT 322 mci radioiodine	Surgery ND RT	NED	4 yr	N/V
Tugcu et al ⁷	F	3	8	5	ALL	RT+C 12 Gy	Surgery	Recurrence 3 month Reoperated After 2 month Surgery ND RT	2 yr	I
Pierre Olivier Vedrine et al ⁸	M	5	9	4	Astrocytoma	RT+C 50 Gy	Surgery	NED	16 yr	I
	M	5	18	13	ALL	RT+C 12 Gy	Surgery	NED	4,5	II
	F	11,5	17	6,5	ALL	RT+C 12 Gy	Surgery	NED	2	I

	F	0.3	9	8	Retioplastoma	RT 52 Gy	Surgery	NED	9 yr	I
	M	11	14	3	Medulloblastma	RT+C 54 Gy	None	Dead		I
	F	5	12	7	Hodgkins	RT+C 20 Gy	Surgery	NED	2	I
	F	4	19,5	15	ALL	RT+C 18 Gy	Surgery RT	NED	2	I
Myer et al ⁹	M	2	10	8	ALL	RT+C 18 Gy	Surgery	NED	2	II
Loy et al ¹⁰	F	9	15	6	ALL	RT+C 18 Gy	Surgery	NED	3	i
	M	1	10	9	AML	RT+C 24 Gy	Surgery	NED	4	I
Sevelli et al ¹¹	F	2	15	13	ALL	RT+C /RT 12 Gy	Surgery	NED	7 yr	I
Arnold et al ¹²	M	20,3	30,9	10,6	Rhabdomyascoma	RT+C 50 Gy RT field not Head and neck	Surgery	NED	13 yr	I
Zidar et al ¹³	F	1	22	21	ALL	RT+C N/V	Surgery	NED	3	I
Piccinelli et al ¹⁴	M	15	24	9	AML	RT+C 12 Gy	RT	NED	3 yr	N/V
Althan et al ¹⁵	F	6	13	7	ALL	RT+C 18 Gy	Surgery ND RT Chemotherapy	NED	2 yr	III
Brito et al ¹⁶	F	48	56	8	Thyroid papillary tumor	RT 150 mic	Surgery	NED	3 yr	I
welstad et al ¹⁷	F	35	67	32	Recurrent sore throat	RT Low dose	Surgery	NED	2	I
	F	15	48	33	Acne	RT Low dose	Surgery RT	NED	2	I
Rice et al ¹⁸	F	16	37	21	Acne	RT 6 Gy	Surgery	NED	2 yr	N/V
Smith et al ¹⁹	F	10	42	32	scar	RT Low dose	Surgery RT	NED	10 mo 1 yr	N/V

LT: Latent time; RT: Radiotherapy.

Table 1: 18 studies included individual patient data that was extractable and fit the minimum criteria for inclusion.

	RT=13	Chemo/RT=27
Gender		
Male	3	14
female	10	13
Initial diagnosis		
malignant	6	27
Benign	7	0
Latent time		
median	27.9	9.78
range	3.5-64	1.3-29
Grade of MEC		
low	7	17
intermediate	3	6
High	0	3
Unknown	3	1

Table 2: Patients characteristics.

cluded radiotherapy for 13 patients and a combination of chemotherapy radiotherapy in 27 patients. The median RT dose delivered was 28, 25 Gy (ranged 6-70 Gy).

Latent time (LT) from Initial Treatment to Development of Mucocoeptidermoid Carcinoma

The median LT recorded from completion of initial treatment to diagnosis of MEC was 11.9 years. LT in RT alone and combination of chemotherapy and RT were 23.7 years and 9.45 years respectively. LT in Chemotherapy-RT group was significantly lesser than LT in patients who were in the Radiotherapy group ($p < 0.01$). LT was 38.7 years (21-64 years) in patients treated for benign conditions relative to 9.7 years (range 3-21 years) in patients treated for malignant conditions (significant at $p < 0.01$). There was no statistically significant difference in LT due to the influence of gender and grade of secondary MEC.

Secondary MEC Carcinoma Properties

Tumor grade was reported in 36 cases. 25 cases (66%) were that of low grade MEC, 6 cases (15%) were that of intermediate MEC, and 3 cases (7.5%) were that of high grade MEC. There was no difference in the grade of secondary MEC with respect to the use of radiotherapy alone or both chemotherapy and radiotherapy ($p < 0.05$).

The secondary MEC was inside or at the edge of the RT field in all the patients who were treated initially with RT alone. For patients who were treated with both RT and chemotherapy, all except one case of secondary MEC developed inside or at the edge of RT field.

Treatment and Outcomes

A majority of patients were treated with surgery alone ($n=27$) 67% or in combination with radiation ($n=10$) 25%. The remaining patients received surgery, combination of chemotherapy and RT ($n=1$), and RT alone ($n=1$).

The median follow-up after diagnosis of secondary MEC was 4.16 years. The overall survival rates over a period of 2 years and 5 years were recorded as 97.5% and 95.4% respectively. One patient was dead of medulloblastoma. There was no statistically significant difference in survival rates with respect to the treatment for the initially diagnosed condition by chemoradiotherapy or by radiotherapy alone.

The overall locoregional control rates recorded over a period of 2 years and 5 years were 97.4% and 93.1% respectively. Local recurrence was seen in 2 patients treated with surgery alone. One patient had intermediate MEC, and the other one had a low grade MEC. There were no regional failures. There was no statistically significant difference in locoregional control with respect to the treatment of initially diagnosed condition i.e., by chemoradiotherapy or by radiotherapy alone.

There was one recorded case of a patient with high grade MEC who developed distant metastasis. One patient with low grade MEC had positive regional lymph node at presentation and was treated with surgery alone. There were no recorded cases of regional failures.

DISCUSSION

The carcinogenic properties of radiation were reported in the early 20th century. Radiation can damage DNA and lead to clinical conditions due to cross-linking between nucleotide bases, and single-stranded and double-stranded breaks in the DNA. The double-stranded DNA breaks and their inappropriate repair may result in mutations. Radiation may also induce mutations of tumor suppressor genes, genomic instability and transmissible instability that maximize the initiation of carcinogenesis. Irradiation may induce development of multiple tumors such as leukemia, carcinoma of mucous membranes, sarcomas, and head and neck carcinoma.⁴

The relationship between irradiation and the head and neck carcinoma has been extensively studied. Saenger reported 11 cases of development of thyroid tumors, 1 case of carcinoma of the parotid and submandibular glands respectively among 1,644 patients who were treated with radiation.²⁰ Epidemiological studies also, have established a link between radiation therapy and the development of salivary gland neoplasms. This relationship has been observed particularly among atomic bomb survivors and patients who underwent radiation therapy for treating benign or neoplastic conditions. There are numerous instances in the literature indicating second malignancies among patients who underwent treatment for childhood neoplasia. However, the number of reported cases for salivary gland tumors was low.⁴ Garwicz et al reviewed the study of 30,000 children undergoing treatment for cancer and identified 247 cases of secondary malignancy, however, only 2 cases of these secondary tumors originated in salivary glands.²¹ Though most studies report salivary gland tumors to be benign, radiation-induced salivary gland tumors are more often associated with malignancies.⁴

Irradiation may induce the formation of benign and malignant tumors of the salivary gland. Benign tumors more commonly occur in the form of pleomorphic adenoma or benign mixed tumor. Malignant tumors are generally identified with MEC, myoepithelial, malignant mixed tumor, adenocarcinoma, acinar carcinoma and acinic cell carcinoma. Modan et al²² reported that the latent time until the development of salivary gland tumor was 11 years in case of malignancies and 21.5 years for the benign condition. The data collected following the study of atomic bomb survivors revealed that the incidence of parotid MEC increased with radiation dose and that MEC was the most common histopathological type observed in salivary gland tumor MEC induced by radiation. A similar observation has also been reported in both the series by Modan et al²² and Beal et al¹

Verma et al³ reported 58 cases of salivary gland MEC

induced by radiation and chemotherapy, most of which were low grade MECS and localized in the parotid gland. He observed that the latency time was shorter in case of the patients treated with chemotherapy +/- radiotherapy versus radiotherapy alone. The overall survival rates recorded over a period of 2 years and 5 years were 98% and 93.4% respectively and the locoregional control rates recorded for over 2 years and 5 years were 97.7% and 92.4% respectively.³

All the patients underwent surgical excision of the primary lesion as indicated by the size and location of the tumor. Neck dissection was performed in selected patients with intermediate and high grade pathology, and post-operative radiation was given to any patient with high grade malignancy, positive margins, or local recurrence. When treated aggressively, the prognosis of these patients appears relatively favorable.⁴ The majority of cases reported for parotid MEC were low grade mucoepidermoid carcinoma, with an excellent prognosis following the complete removal of the tumor.³

This meta-analysis is limited due to small number of cases and the incomplete data found in the studies included that may prevent reaching statistically significant results. Although data heterogeneity might better reflect overall global population trends and enable generalization of the findings, many of the included studies have relatively small populations, which subject the analysis to publication bias. This may result in an over- or underestimation of treatment effect.

CONCLUSION

Radiation induced parotid MEC was most commonly diagnosed among females. In most of the reported cases, the initial diagnosis indicated the occurrence of ALL, acne and Hodgkins lymphoma. The latent time for secondary MEC development was significantly shorter in chemotherapy and radiotherapy groups. A majority of patients were treated with surgery alone (n=27) (67%) or in combination with radiation therapy (n=10) (25%). The overall survival rates recorded over a period of 2 years and 5 years were 97.5% respectively and the locoregional control rates recorded over a period of 2 years and 5 years were 97.4% and 93.1% respectively. There was no statistically significant difference in the survival or locoregional control rates between the groups exposed to radiation or a combination of chemotherapy and radiation. There was one recorded case of a patient with high grade MEC who developed distant metastasis. Also, the study indicated one patient with low grade MEC with positive regional lymph node at presentation who was treated with surgery alone. Only 1 case of patient death has been reported on account of medulloblastoma. There has been no evidence of regional failures.

REFERENCES

1. Beal KP, Singh B, Kraus D, Yahalom J, Portlock C, Wolden SL. Radiation-induced salivary gland tumors: A report of 18 cases and a review of the literature. *Cancer J*. 2003; 9(6): 467-471.

Web site. <https://www.ncbi.nlm.nih.gov/pubmed/14740975>. Accessed November 17, 2016.

2. Prasannan L, Pu A, Hoff P, Weatherly R, Castle V. Parotid carcinoma as a second malignancy after treatment of childhood acute lymphoblastic leukemia. *J Pediatr Hematol Oncol*. 1999; 21(6): 535-538. Web site. <https://www.ncbi.nlm.nih.gov/pubmed/10598668>. Accessed November 17, 2016.

3. Verma J, Teh BS, Paulino AC. Characteristics and outcome of radiation and chemotherapy-related mucoepidermoid carcinoma of the salivary glands. *Pediatr Blood Cancer*. 2011; 57(7): 1137-1141. doi: [10.1002/pbc.22978](https://doi.org/10.1002/pbc.22978)

4. Whatley WS, Thompson JW, Rao B. Salivary gland tumors in survivors of childhood cancer. *Otolaryngol Head Neck Surg*. 2006; 134(3): 385-388. doi: [10.1016/j.otohns.2005.10.022](https://doi.org/10.1016/j.otohns.2005.10.022)

5. Rodríguez-Cuevas S, Ocampo LB. A case report of mucoepidermoid carcinoma of the parotid gland developing after radioiodine therapy for thyroid carcinoma. *Eur J Surg Oncol*. 1995; 21(6): 692. Web site. <https://www.ncbi.nlm.nih.gov/pubmed/8631425>. Accessed November 17, 2016.

6. Henze M, Hittel JP, Elser H. [Mucoepidermoid carcinoma of the submandibular gland after high-dose radioiodine therapy: Case report and review of the literature]. *Nuklearmedizin*. 1998; 37(1): 45-49. Web site. <https://www.ncbi.nlm.nih.gov/pubmed/9467170>. Accessed November 17, 2016.

7. Tugcu D, Akici F, Aydogan G, et al. Mucoepidermoid carcinoma of the parotid gland in childhood survivor of acute lymphoblastic leukemia with need of radiotherapy for treatment and review of the literature. *Pediatr Hematol Oncol*. 2012; 29(4): 380-385. doi: [10.3109/08880018.2012.673696](https://doi.org/10.3109/08880018.2012.673696)

8. Thariat J, Veldre PO, Temam S, et al. The role of radiation therapy in pediatric mucoepidermoid carcinomas of the salivary glands. *J Pediatr*. 2013; 162(4): 839-843. doi: [10.1016/j.jpeds.2012.09.045](https://doi.org/10.1016/j.jpeds.2012.09.045)

9. Myer C, Cotton RT. Salivary gland disease in children: a review. Part 2: Congenital lesions and neoplastic disease. *Clin Pediatr (Phila)*. 1986; 25(7): 353-357. Web site. <https://www.ncbi.nlm.nih.gov/pubmed/3709019>. Accessed November 17, 2016.

10. Loy TS, McLaughlin R, Odom LF, Dehner LP. Mucoepidermoid carcinoma of the parotid as a second malignant neoplasm in children. *Cancer*. 1989; 64(10): 2174-2177. doi: [10.1002/pbc.20306](https://doi.org/10.1002/pbc.20306)

11. Savelli SL, Klopfenstein KJ, Termuhlen AM. Mucoepidermoid carcinoma of the parotid gland as a second malignant neoplasm. *Pediatr Blood Cancer*. 2005; 45(7): 997-1000. doi: [10.1002/pbc.20306](https://doi.org/10.1002/pbc.20306)

12. Paulino AC, Fowler BZ. Secondary neoplasms after radiotherapy for a childhood solid tumor. *Pediatric Hematology and Oncology*. 2005; 22(2): 89-101, doi: [10.1080/08880010590896459](https://doi.org/10.1080/08880010590896459)
13. Zidar N, Gale N, Zupevc A, Zargi M. Salivary gland tumours as second neoplasms: Two cases and literature review. *J Laryngol Otol*. 2010; 124(5): 577-580. doi: [10.1017/S0022215109991526](https://doi.org/10.1017/S0022215109991526)
14. Piccinelli KJ, Taj M, Lucraft HH, Skinner R. Secondary parotid mucoepidermoid carcinoma after TBI and chemotherapy in childhood AML. *Pediatr Blood Cancer*. 2006; 47(3): 345-346. doi: [10.1002/pbc.20832](https://doi.org/10.1002/pbc.20832)
15. Atahan IL, Ayhan A, Ozyar E, Ertoy D, Gürkaynak M. A case of mucoepidermoid carcinoma of the parotid gland developing in a child after the treatment of acute lymphoblastic leukemia. *Pediatr Hematol Oncol*. 1995; 12(4): 403-405. doi: [10.3109/08880019509029592](https://doi.org/10.3109/08880019509029592)
16. Brito M, Block-Galarza J. Case Report: Mucoepidermoid Carcinoma of the Parotid Gland after Radioiodine Therapy For Thyroid Cancer. Albany, NY, USA: Albany Medical Center and Albany Medical College. Web site. https://www.amc.edu/academic/gme/programs/Endocrinology/documents/mucoepid_-_brito.pdf. Accessed November 17, 2016.
17. Swelstad JA, Scanlon EF, Oviedo MA, Hugo NE. Irradiation-induced polyglandular neoplasia of the head and neck. *Am J Surg*. 1978; 135: 820-824. Web site. <https://www.ncbi.nlm.nih.gov/pubmed/149506>. Accessed November 17, 2016.
18. Rice DH, Batsakis JG, McClatchey RD. Post-irradiation of malignant salivary gland tumors. *Arch Otolaryngol*. 1976; 102: 699-701. Web site. <https://www.ncbi.nlm.nih.gov/pubmed/985205>. Accessed November 17, 2016.
19. Smith DG, Levitt SH. Radiation carcinogenesis: An unusual familial occurrence of neoplasia following irradiation in childhood for benign disease. *Cancer*. 1974; 4: 2069-2071. Web site. <https://www.ncbi.nlm.nih.gov/pubmed/4373164>. Accessed November 17, 2016.
20. Saenger EL, Silverman FN, Sterling TD, Turner ME. Neoplasm following therapeutic irradiation for benign conditions in childhood. *Radiology*. 1960; 74: 889-904. doi: [10.1148/74.6.889](https://doi.org/10.1148/74.6.889)
21. Garwicz S, Anderson H, Olsen JH, et al. Second malignant neoplasms after cancer in childhood and adolescence: A population-based case-control study in the 5 Nordic countries. The Nordic Society for Pediatric Hematology and Oncology. The Association of the Nordic Cancer Registries. *Int J Cancer*. 2000; 88(4): 672-678. doi: [10.1002/1097-0215\(20001115\)88:4<672::AID-IJC24>3.0.CO;2-N](https://doi.org/10.1002/1097-0215(20001115)88:4<672::AID-IJC24>3.0.CO;2-N)
22. Modan B, Chetrit A, Alfandary E, et al. Increased risk of salivary gland tumors after low-dose irradiation. *Laryngoscope*. 1998; 108(7): 1095-1097. Web site. <https://www.ncbi.nlm.nih.gov/pubmed/9665263>. Accessed November 17, 2016.