Openventio PUBLISHERS

ISSN 2377-8369

GASTRO

Open Journal

February, 2015 • Volume 1, Issue 1

www.openventio.org

GASTRO

Openventio PUBLISHERS

ISSN 2377-8369

Open Journal

TABLE OF CONTENTS

GASTRO

Openventio PUBLISHERS

ISSN 2377-8369

Open Journal

http://dx.doi.org/10.17140/GOJ-1-101

Case Report

*Corresponding author:
Fabio Pagni, MD
Department of Surgery and Interdisciplinary Medicine Pathology
University Milan Bicocca
San Gerardo Hospital
20900, Monza, Italy
E-mail: Fabio.pagni@unimib.it

Volume 1 : Issue 1
Article Ref. #: 1000GOJ1101

Article History:
Received: April 24th, 2014
Accepted: May 20th, 2014
Published: May 29th, 2014

Citation:
Jaconi M, Frego R, Pagni F. Duodenal Amyloidotic Tumor. *Gastro Open J*. 2014; 1(1): 1-2.

Duodenal Amyloidotic Tumor

Marta Jaconi[1], Roberto Frego[2] and Fabio Pagni[1*]

[1]*Department of Pathology, University Milan Bicocca, San Gerardo Hospital, Monza, Italy*

[2]*Endoscopy Unit, San Gerardo Hospital, Monza, Italy*

DESCRIPTION OF THE CASE

This duodenal polypoid lesion was found during Esophago Gastro Duodenoscopy (EGDS) performed in a 77-year-old woman (Figure 1A). Our patient had already been diagnosed with multiple myeloma a few years earlier; although treated with multiple lines of treatment, the disease was still in progression with multiple vertebral localizations and renal failure. She started complaining of asthenia and suffered from various episodes of melena over two weeks; the Emergency Room assessment found Deep Venous Thrombosis (DVT) and severe anemization (Hb 5.9 g/dl). After stabilization with 3 blood transfusions, she underwent an EGDS to localize the source of bleeding. The polypoid lesion that was found underwent biopsy because it raised suspicions of localization of myeloma, primary tumor of the duodenum or infectious disease. Histology, instead, excluded the presence of a neoplastic tumor, but revealed massive mucosal and submucosal deposits of an amorphous eosinophilic substance (Figure 1B), that showed apple-green birefringence on staining with Congo red (Figures 1C and 1D). A diagnosis of tumoral intestinal AL amyloidosis was made.

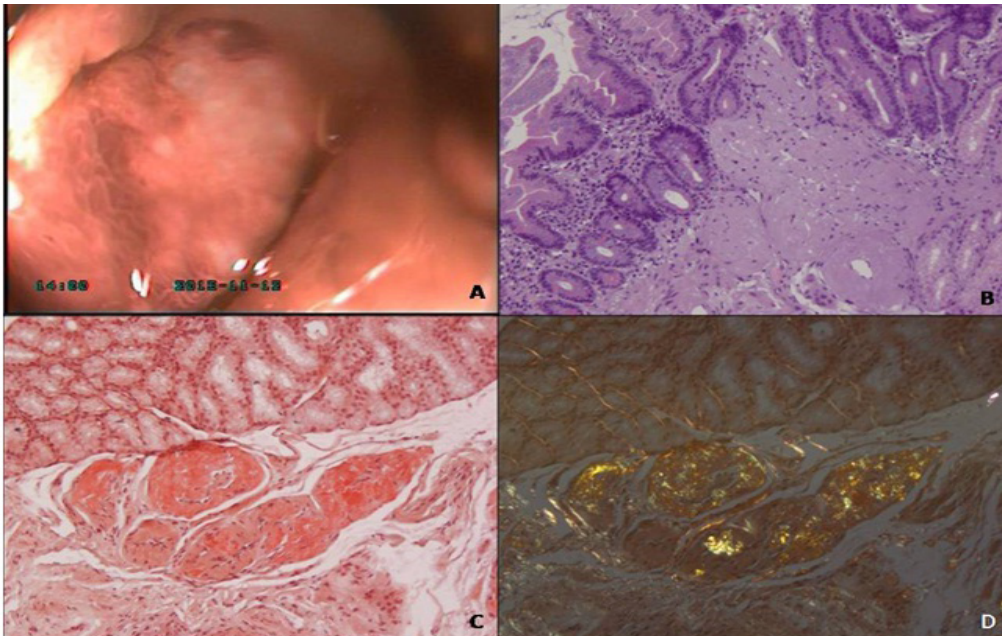

Figure 1: A: Endoscopic appearance of this duodenal polypoid vegetant lesion; B: Haematoxylin & Eosin stain revealed absence of malignancy; the pseudotumoral appearance was due to the presence of abundant amorphous material consistent with amyloid; C-D: Congo Red histochemistry confirmed the morphological suspicion.

DISCUSSION

Primary amyloidosis is the most common form of amyloidosis and the only form that occurs with multiple myeloma. It is caused by fragments of abnormal antibodies (light

chains). Amyloid can form deposits in loidosis and the only form that occurs with multiple myeloma. It is caused by fragments of abnormal antibodies (light chains). Amyloid can form deposits in different organs such as kidneys, liver, myocardial tissue, skin and peripheral nervous system; our patient lacked involvement of these typical organs. Gastrointestinal (GI) involvement is quite rare, occurring in approximately 8% of patients,[1] and often subclinical. The mass-forming pattern is even rarer, as in the majority of cases the deposits are linear, presenting themselves as mucosal thickening and enlarged folds.[2] The most common symptoms of GI amyloidosis are weight loss, diarrhea, malabsorption, pseudo-obstruction, perforation and gastrointestinal bleeding, associated with vascular friability.[3,4] At endoscopy, GI amyloidosis can mimic many benign and malignant diseases, including ulcerative, flat or vegetant tumours. Only the histological examination allows the formulation of a correct diagnosis and a proper treatment, particularly in these solitary presentations.[5] We report this case as an example of an uncommon but peculiar diagnostic pitfall, which in literature has been referred to as "amyloidoma". Amyloidotic tumors, being able to trick both clinical examination and imaging, share this feature with other non- neoplastic lesions such as GI xanthomas, inflammatory and lymphoid polyps, heterotopic gastric or pancreatic tissues.[6] All these occurrences have also in common the need for biopsies in order to establish their true nature. However, patients with GI amyloidosis and evidence of active GI bleeding or ulceration are not offered myeloablative chemotherapy, because of the risk of catastrophic GI hemorrhage.[7] Patients who are not candidates for chemoterapic regimens, are usually treated in clinical trials with novel agents or with melphalan and dexamethasone.[7]

REFERENCES

1. Menke DM, Kyle RA, Fleming CR, Wolfe JT. Symptomatic gastric amyloidosis in patients with primary systemic amyloidosis. *Mayo Clin Proc*. 1993; 68(8): 763-767. doi: 10.1016/S0025-6196(12)60634-X

2. Rivera R, Kaul V, DeCross A, Whitney-Miller C. Primary gastric amyloidosis presenting as an isolated gastric mass. *Gastrointestinal Endoscopy*. 2012; 76: 186-187. doi: 10.1016/j.gie.2012.02.059

3. Gould M, Zarrin-Khameh N, Sellin J. Small bowel amyloidosis. *Curr Gastroenterol Rep*. 2013; 15(10): 350. doi: 10.1007/s11894-013-0350-4

4. Sawada T, Adachi Y, Akino K, et al. Endoscopic features of primary amyloidosis of the stomach. *Endoscopy*. 2012; 44: s2: 275-276. doi: 10.1055/s-0032-1309750

5. Ali MF, Patel A, Muller S, Friedel D. Rare presentation of primary (AL) amyloidosis as gastrointestinal hemorrhage without systemic involvement. *World J Gastrointest Endosc*. 2014; 6(4): 144-147. doi: 10.4253/wjge.v6.i4.144

6. Sattianayagam P, Hawkins P, Gillmore J. Amyloid and the GI tract. *Expert Rev Gastroenterol Hepatol*. 2009; 3(6): 615-630. doi: 10.1586/egh.09.59

7. Cowan AJ, Skinner M, Seldin DC, et al. Amyloidosis of the gastrointestinal tract: a 13-year, single-center, referral experience. *Haematologica*. 2013; 98(1): 141-146. doi: 10.3324/haematol.2012.068155

GASTRO

Openventio PUBLISHERS

ISSN 2377-8369

Open Journal

http://dx.doi.org/10.17140/GOJ-1-102

Case Report

*Corresponding author:
Renato Caviglia, MD, PhD
Department of Gastroenterology and Digestive Endoscopy, Jewish Hospital of Rome, Via Fulda 14, Rome 00100, Italy
E-mail: renatocaviglia@gmail.com

Volume 1 : Issue 1
Article Ref. #: 1000GOJ1102

Article History:
Received: May 6th, 2014
Accepted: June 27th, 2014
Published: July 16th, 2014

Citation:
Caviglia R, Di Castro A, Cannaviello C, Lippi B. Fistulizing Crohn's disease complicated by hidden retroperitoneal abscess: a case report and review of the literature. *Gastro Open J*. 2014; 1(1): 3-6.

Fistulizing Crohn's Disease Complicated by Hidden Retroperitoneal Abscess: A Case Report and Review of the Literature

Renato Caviglia[1*], Angelo Di Castro[2], Claudio Cannaviello[1] and Basilio Lippi[3]

[1]*Department of Gastroenterology and Digestive Endoscopy, Jewish Hospital of Rome. Via Fulda 14, Rome 00100, Italy*

[2]*Department of Oncological Surgery, Ospedale San Camillo-Forlanini. Via Portuense 332, Rome 00151, Italy*

[3]*Department of Radiology, Jewish Hospital of Rome. Via Fulda 14, Rome 00100, Italy*

ABSTRACT

Crohn's Disease (CD) is a chronic inflammatory disorder of the intestinal tract characterized by trans-mural damage of the bowel wall often complicated by strictures, entero-visceral and perianal fistulae and abscesses. Both computed tomography and magnetic resonance enable clear visualization of the involved intestinal tract together with various extra- and intra-intestinal complications. Herewith, the uncommon case of a hidden retroperitoneal abscess with para-vertebral collection, as a consequence of a penetrating CD of the terminal ileum, is described. Retrofascial collections, due to fistulizing CD, are rare events often misdiagnosed or even recognized late in the clinical course and associated with severe and potentially life-threatening consequences. Prompt assessment with cross-sectional imaging is necessary. MR imaging is being more frequently used in the follow-up of CD since the lack of ionizing radiations which avoids any biological impact in these patients.

KEYWORDS: Crohn's disease; Inflammatory bowel disease; Intestinal tract.

ABBREVIATIONS: CRP: C-reactive protein; CD: Crohn's Disease; CT: Computed Tomography; ESR: Erythrocyte Sedimentation Rate; GI: Gastrointestinal; MR: Magnetic Resonance; MRI: Magnetic Resonance Imaging.

CASE REPORT

A 30-year-old female with a 3-year history of Crohn's Disease (CD) of the terminal ileum and complaining recently of a 3-week progressive abdominal pain, nausea and diarrhea (5-6 bowel movements/day) was admitted to the hospital. The patient was febrile (37.5 °C) and presented right lumbar pain radiating to the gluteus region. The patient had been treated with methotrexate, mesalazine and metronidazole over the previous 6 months.

Upon presentation, the abdominal examination revealed normal bowel sounds and abdominal tenderness without rebound. A mass, 7 cm by 3 cm, was palpated in the lower right quadrant, which was tender to palpation, without guarding, rebound or tap tenderness. The remainder of the examination was normal. Blood tests showed moderate leucocytosis and an increase both in Erythrocyte Sedimentation Rate (ESR) and C-reactive protein (CRP) levels

ISSN 2377-8369 Open Journal http://dx.doi.org/10.17140/GOJ-1-102

were observed. Results are shown in Table 1.

Erythrocyte count (x10^{6}mm^3) (range 3,800-4,800)	3,750
Hematocrit (%) (range 34-42)	38
Hemoglobin (g/dl) (range 11.5-13.5)	11
White-cell count (mm^3) (range 5,000-9,000)	10,500
Neutrophils (%) (range 30-65)	87
Lymphocytes (%) (range 30-48)	22
Platelet count (mm^3) (range 150,000-450,000)	345,000
Mean corpuscular volume (µm^3) (range 77-95)	87
Erythrocyte sedimentation rate (mm/hr) (range 0-25)	65
C-reactive protein (mg/dl) (range 0.01-0.05)	18

Table 1: Laboratory data

Magnetic Resonance (MR) enterography was performed which revealed thickness of the terminal ileum wall, with associated fistulae from the ileocecal valve to the retroperitoneal and retrofascial space (Figure 1-3); The presence of a large fluid

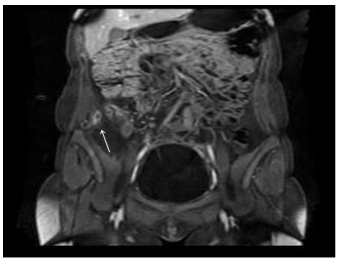

Figure 1: A 30-year-old female with a 3-year history of Crohn's disease of the terminal ileum. Coronal MRI (GE Echospeed 1.5 T HD), T1 post-gadolinium (MultiHance) demonstrates thickening of the ileum wall and perivisceral fistulae.

Figure 2: A 30-year-old female with a 3-year history of Crohn's disease of the terminal ileum. Coronal plane MRI (GE Echospeed 1.5 T HD), T1 post-gadolinium (MultiHance) demonstrates an abscess in the right retroperitoneal space, below the right kidney.

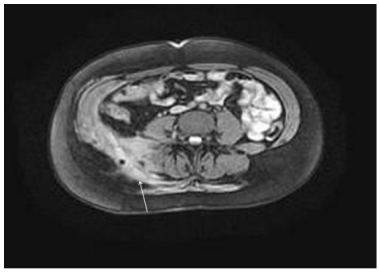

Figure 3: A 30-year-old female with a 3-year history of Crohn's disease of the terminal ileum. Axial MRI (GE Echospeed 1.5 T HD), T1 post-gadolinium (MultiHance) demonstrates an abscess in the right retroperitoneal and para-vertebral space with enhancement of the walls.

collection was detected in this area. Computed Tomography (CT) was performed to further investigate these findings which revealed, in the retrofascial space, an abscess measuring 6 cm by 5 cm filled with air and fluid (Figure 4).

Figure 4: A 30-year-old female with a 3-year history of Crohn's disease of the terminal ileum. Axial CT with contrast (Ultravist 370) in the portal venous phase (GE Optima 660, 1.5 mm slice thickness, 120 mVp, 200 mAs) demonstrates thickening of the right para-vertebral muscles containing a gas bubble.

Immunomodulators were immediately withdrawn and antibiotic therapy was started administering intravenous (iv) metronidazole and ciprofloxacin. The patient underwent abdominal surgery. An ileocolectomy was performed with a latero-lateral ileocolonic anastomosis. Unfortunately, when the surgeons performed the laparotomy they weren't able to localize the collection which was deeply located in the retroperitoneal space, close to the spinal column. So, after the surgery, the patient underwent an ultrasound study which revealed thickening of the right para-vertebral muscles and a hypoechoic abscess in the posterior soft tissue. Thereafter, a CT-guided percutaneous drainage of the retroperitoneal abscess was performed and approximately 300 ml of purulent fluid were aspirated and a drain was placed therein. Ampicillin, gentamicin and metronidazole were administered iv. Gram's staining of the aspirate revealed abundant polymorphonuclear leukocytes, gram-negative and gram-positive rods and moderate gram-positive cocci in pairs.

Following surgery and percutaneous drainage, body temperature returned to normal within 3 days. Six weeks after discharge, immunosuppressive therapy was reintroduced with good clinical results.

DISCUSSION

CD is a chronic inflammatory disorder which may involve any segment of the Gastrointestinal (GI) tract and which is characterized by trans-mural damage of the bowel wall.[1] The incidence of CD is approximately 5-10 new cases per 100,000 individuals/year and is known to follow an unpredictable course with periodic exacerbations.[2] Although the terminal ileum is the most common site of CD and upper GI involvement is rare, multiple non-contiguous segments of the small bowel may be involved.[3] Since CD is characterized by a trans-mural inflammatory process, leading to symptomatic strictures, the differentiation between a prevalent inflammatory or fibromatous process is often difficult but is essential for appropriate clinical management (i.e., medical *vs.* surgical treatment).[4]

MRI provides a definite soft tissue contrast resolution enabling a good visualization of the inflammatory and

ISSN 2377-8369 Open Journal http://dx.doi.org/10.17140/GOJ-1-102

fibrotic characteristics of the bowel wall. Normal bowel thickness is considered to be ≤3 mm.[5] With time, common complications of small-bowel CD may include bowel obstructions, fistulae and abscesses.

Fistulae may act as a bridge to adjacent loops of the small bowel or from the small bowel to the colon, stomach, bladder and skin. In population based studies, fistula formation has been reported in 17-50% of patients with CD.[1,2] According to an epidemiologic study, 35% of the CD patients develop at least one fistula episode during the course of the disease. Of these fistulae, approximately two thirds are external (perianal 55%, enterocutaneous 6%) and one third are internal.[2] Penetrating disease may cause the formation of abscesses which can often be treated by a percutaneous approach. The presence of penetrating disease, in the absence of a collection, often influences the medical approach; clinicians, usually avoid the use of steroids in such cases and may, instead, consider antibiotic or biologic therapy.

Fistulae occur as the result of deep transmural ulcers or fissures that eventually penetrate the bowel layers and cause inflammation in the adjacent mesenteric tissue leading to formation of small abscesses and blind-ending sinus tracts. Upon CT and MRI, fistulae appear as extra-enteric enhancing tracts which may or may not contain fluid.

Recent advances in CT and MR imaging (MRI) offer excellent visualization of the small bowel wall and lumen when the organ is appropriately distended using an enteric contrast. In particular, these techniques can reveal small bowel inflammation and complications (e.g., strictures, fistulae, abscesses).[6] Furthermore, MRI is becoming more and more important as a diagnostic tool in the work-up of CD, given the lack of ionizing radiations, considering that these examinations are performed frequently during the follow-up of these patients. Several studies have also shown that the MRI technique defines not only the site but also the degree of CD activity, by evaluating the increased enhancement of the involved bowel wall by means of contrast T1-weighted sequences.[6-12] Horsthuis et al. performed a meta-analysis and reported that there was no statistically significant difference between MRI and CT in the detection of inflammatory bowel disease, including extra-enteric complications.[13]

The retroperitoneal abscess is a relatively rare condition and is often misdiagnosed or even recognized late in the clinical course. It is a severe infection which is associated with significant mortality but early diagnosis and treatment considerably reduce the morbidity and mortality rates. Recognition of the condition and the likely etiological factors would increase awareness and, therefore, early surgical drainage would significantly improve clinical outcome.

Herewith, we presented an illustrative case of fistulizing CD complicated by a retro-peritoneal abscess. The retroperitoneum is a space between the peritoneum and *transversalis* fascia which lines the posterior abdominal cavity. It extends laterally to the edges of the *quadratus* lumbar muscles, the diaphragm above and the pelvic brim below. The retroperitoneum is divided into an anterior space containing the colon, duodenum, and pancreas and a posterior space in which kidneys, aorta, and inferior vena cava are found. The area is closed above but is open below thus allowing retro-peritoneal infections to be bilateral and extend to the pelvis and thighs. The retrofascial space which is located between the *transversalis* fascia and the posterior parietal wall contains the spinal and para-vertebral musculature. This area extends above into the mediastinum and below into the pelvis and thighs. Infections of the retrofascial area that are not strictly in the retroperitoneal space are included in the differential diagnosis of the retro-peritoneal abscess. Thus, infections and inflammatory processes of any of these anatomical structures may result in a retro-peritoneal abscess. Abscesses resulting from deep fissuring of the bowel wall or suppuration within lymph nodes and local fistulation, develop in approximately 20% of CD patients.[1,2] Several cases of vertebral and para-vertebral infection have been described in association with enteric fistulae.[14] Isolated discitis, however, has rarely been reported.

In conclusion, we describe the unusual case of a hidden retroperitoneal abscess with para-vertebral collection as a consequence of a penetrating CD of the terminal ileum, emphasizing the importance of complete radiological work-up in these patients and the need for a careful clinical and surgical evaluation in order to define the most appropriate medical treatment in such cases.

AUTHORS' CONTRIBUTIONS

Renato Caviglia and Basilio Lippi contributed equally to this article. Angelo Di Castro and Claudio Cannaviello collected the medical data and read and approved the manuscript.

ACKNOWLEDGEMENTS

The Authors are grateful to Mrs. Marian Shields for helping with the preparation of the manuscript as well as the language.

DISCLOSURES

The authors have no conflicts of interest to declare.

CONSENT

Did the authors obtain written informed consent from the patient for submission of this manuscript for publication? Yes

REFERENCES

1. Fiocchi C. Inflammatory bowel disease: evolutionary concepts in biology, epidemiology, mechanisms and therapy. *Curr Opin Gastroenterol*. 2013; 29(4): 347-349. doi: 10.1097/MOG.0b013e3283622b73

2. Loftus EV Jr, Sandborn WJ. Epidemiology of inflammatory bowel disease. *Gastroenterol Clin North Am*. 2002; 31(1): 1-20.

3. Annunziata ML, Caviglia R, Papparella LG, Cicala M. Upper gastrointestinal involvement of Crohn's disease: a prospective study on the role of upper endoscopy in the diagnostic work-up. *Dig Dis Sci*. 2012; 57(6): 1618-1623. doi: 10.1007/s10620-012-2072-0

4. Rieder F, Zimmermann EM, Remzi FH, Sandborn WJ. Crohn's disease complicated by strictures: a systematic review. *Gut*. 2013; 62(7): 1072-1084. doi: 10.1136/gutjnl-2012-304353

5. Amitai MM, Ben-Horin S, Eliakim R, Kopylov U. Magnetic resonance enterography in Crohn's disease: A guide to common imaging manifestations for the IBD physician. *J Crohns Colitis*. 2013; 7(8): 603-615. doi: 10.1016/j.crohns.2012.10.005

6. Del Vescovo R, Sansoni I, Caviglia R, et al. Dynamic contrast enhanced magnetic resonance imaging of the terminal ileum: differentiation of activity of Crohn's disease. *Abdom Imaging*. 2008; 33(4): 417-424. doi: 10.1007/s00261-007-9267-4

7. Maccioni F, Viscido A, Broglia L, et al. Evaluation of Crohn's disease activity with magnetic resonance imaging. *Abdom Imaging*. 2000; 25(3): 219-228.

8. Koh DM, Miao Y, Chinn RJ, et al. MR imaging evaluation of the activity of Crohn's disease. *AJR Am J Roentgenol*. 2001; 177(6): 1325-1332.

9. Born C, Nagel B, Leinsinger G, Reiser M. MRI with oral filling in patients with chronic inflammatory bowel diseases. *Radiologe*. 2003; 43(1): 34-42. doi: 10.1007/s00117-002-0830-2

10. Schunk K, Kern A, Oberholzer K, et al. Hydro-MRI in Crohn's disease: appraisal of disease activity. *Invest Radiol*. 2000; 35(7): 431-437.

11. Laghi A, Borrelli O, Paolantonio P, et al. Contrast enhanced magnetic resonance imaging of the terminal ileum in children with Crohn's disease. *Gut*. 2003; 52(3): 393-397.doi: 10.1136/gut.52.3.393

12. Low RN, Francis IR, Politoske D, Bennett M. Crohn's disease evaluation: comparison of contrast-enhanced MR imaging and single-phase helical CT scanning. *J Magn Reson Imaging*. 2000; 11(2): 127-135. doi: 10.1002/(SICI)1522-2586(200002)11:2<127::AID-JMRI8>3.0.CO;2-G

13. Horsthuis K, Bipat S, Bennink RJ, Stoker J. Inflammatory bowel disease diagnosed with US, MR, scintigraphy and CT: meta-analysis of prospective studies. *Radiology*. 2008; 247(1): 64-79. doi: 10.1148/radiol.2471070611

14. Tonolini M, Ravelli A, Campari A, Bianco R. Comprehensive MRI diagnosis of sacral osteomyelitis and multiple muscle abscesses as a rare complication of fistulizing Crohn's disease. *J Crohn's Colitis*. 2011; 5(5): 473-476. doi: 10.1016/j.crohns.2011.04.009

GASTRO

Openventio PUBLISHERS

ISSN 2377-8369

Open Journal

http://dx.doi.org/10.17140/GOJ-1-103

Review

*Corresponding author:
Maristella Adami, PhD
Department of Neuroscience
University of Parma
Via Volturno 39
43125 Parma Italy
Tel. +39 0521 903943
Fax: +39 0521 903852
E-mail: maristella.adami@unipr.it

Volume 1 : Issue 1
Article Ref. #: 1000GOJ1103

Article History:
Received: May 30th, 2014
Accepted: June 12th, 2014
Published: July 16th, 2014

Citation:
Adami M, Coruzzi G. The Histamine H4 Receptor: a novel target for safe anti-inflammatory drugs?. *Gastro Open J.* 2014; 1(1): 7-12.

The Histamine H_4 Receptor: A Novel Target for Safe Anti-inflammatory Drugs?

Maristella Adami* and Gabriella Coruzzi[1]

Department of Neuroscience, University of Parma, Via Volturno 39, 43125 Parma, Italy

[1]retired

ABSTRACT

The functional role of histamine H_4 receptors (H_4Rs) in the Gastrointestinal (GI) tract is reviewed, with particular reference to their involvement in the regulation of gastric mucosal defense and inflammation. H_4Rs have been detected in different cell types of the gut, including immune cells, paracrine cells, endocrine cells and neurons, from different animal species and humans; moreover, H_4R expression was reported to be altered in some pathological conditions, such as colitis and cancer. Functional studies have demonstrated protective effects of H_4R antagonists in several experimental models of gastric mucosal damage and intestinal inflammation, suggesting a potential therapeutic role of drugs targeting this new receptor subtype in GI disorders, such as allergic enteropathy, Inflammatory Bowel Disease (IBD), Irritable Bowel Syndrome (IBS) and cancer.

KEYWORDS: Histamine H_4 receptor; Stomach; Intestine.

ABBREVIATIONS: CNS: Central Nervous System; GI: Gastrointestinal; H_3Rs: H_3 Receptors; H_4Rs: H_4 Receptors; IBD: Inflammatory Bowel Disease; IBS: Irritable Bowel Syndrome; IL-6: Interleukin-6; NSAIDs: Nonsteroidal Anti-inflammatory Drugs; TNBS: Trinitrobenzene Sulphonic Acid; TNF-α: Tumour Necrosis Factor-alpha; UC: Ulcerative Colitis.

INTRODUCTION

After the discovery of histamine H_2 receptors and their revolutionary role in the therapy of gastroduodenal ulcer,[1-3] the research on Gastrointestinal (GI) histamine was considered to be settled. However, renewed interested in the amine emerged in the '90s with the discovery of the histamine H_3 receptor (H_3R),[4,5] and subsequently, in the early 2000 when the H_4 receptor (H_4R) was detected from the human genome database by several independent groups.[6-8] As a consequence, novel therapeutic fields have been unravelled for antihistamine drugs: whereas histamine H_3R antagonists may represent new therapeutic options for cognitive, sleep and memory disorders[5,9] and for obesity,[10] H_4R antagonists are currently the object of intensive research, as potential candidates in the therapy of allergy, inflammatory disorders, neurophatic pain and pruritus.[7,11,12]

The present review will focus on the location and functional role of H_4Rs in the GI tract and the potential clinical implications for human diseases. Beneficial effects of H_4R blockers at GI level would be of particular interest, when considering that the available Nonsteroidal Anti-inflammatory Drugs (NSAIDs) are still endowed with significant gastric and intestinal toxicity.[13-14] This is particularly true for the still unrecognized NSAID-induced enteropathy, which occurs frequently and still awaits for medical treatment.[15-16]

ISSN 2377-8369 Open Journal http://dx.doi.org/10.17140/GOJ-1-103

THE HISTAMINE H_4R

The H_4R is a G-protein coupled receptor which has been primarily detected outside the Central Nervous System (CNS), and, in particular, in immune and inflammatory cells, including mast cells, eosinophils, basophils, dendritic cells and T cells.[6-8] This has led to hypothesize for the H_4R a key role in inflammation and immunoregulation. Indeed, a variety of *in vitro* data have shown that H_4Rs are involved in the control of chemotactic response and cytoskeletal changes of human eosinophils, mast cell chemotaxis and release of interleukin-16 from human CD8+ T cells and dendritic cell migration.[7-8,17] Functional *in vivo* studies in rodents have confirmed anti-inflammatory, antihyperalgesic and antiallergic effects of selective H_4R antagonists in a variety of acute and chronic experimental models.[18-24]

HISTAMINE H_4R LIGANDS

Since H_3R and H_4R are closely related, the early physio-pharmacological characterization of the H_4R was based on compounds retaining the ability to bind the H_3R subtype.[25] The first selective H_4R antagonist was the indolylpiperazine compound, JNJ7777120, which displayed high affinity (K_i= 4 nM) for the human H_4R with and a >1000-fold selectivity over the other histamine receptors,[26] thus becoming the "reference" H_4R ligand in most experimental assays, also due to the lack of highly selective H_4R agonists.[27,28] To complicate matters, the subsequent availability of chemically different H_4R ligands showed that several compounds could display a protean activity, behaving as full agonists, partial agonists or actually neutral antagonists, depending on the functional assay.[29-32] Indeed, some pharmacological discrepancies have recently emerged: H_4R activation, rather than blockade, was found to display anti-inflammatory or protective effects,[30-32] and on the other hand, the "standard" H_4R antagonist JNJ7777120 was found to behave as an agonist in some experimental assays.[29-31] The use of non selective compounds (i.e. mixed H_3/H_4 receptor ligands) and the occurrence of strain-dependent effects of H_4R ligands[33] may further contribute to an erroneous interpretation of experimental data and make the characterization of H_4R function a great challenge for histaminologists. Human studies are therefore highly recommended. Unfortunately, so far, only few compounds have entered into clinical trials: JNJ-39758979 in phase II for itch and asthma, ZPL-38937887 (PalauPharma) in phase I, UR-63325 (PalauPharma) in phase I with excellent safety and profile.[34]

LOCATION OF H_4Rs IN THE GI TRACT

H_4R expression was found throughout the GI tract of different animal species and humans.[35] As shown in Table 1, the expression was unraveled both in normal tissues and under pathological conditions, such as esophagitis and colitis;[36-49] a decrease in H_4R density was reported in human gastric and colorectal carcinoma.[39,55-56] Cell types expressing H_4R include immune and inflammatory cells, epithelial cells and neurons of the myenteric and submucous plexus. Interestingly, H_4R expression was found in ghrelin-producing cells of the rat stomach,[37] leading to speculation about a possible role of histamine in the secretion of the orexigenic peptide.

Tissue	Normal/Pathological	Species	Ref.
Oesophagus	eosinophilic esophagitis	guinea pig	36
Stomach	normal	rat	37
	normal	human	38, 39
	carcinoma	human	39
Small intestine	normal	mouse	40
	normal	rat	41
	normal	dog	42
	normal	human	38,43-47
Colon	spontaneous colitis	mouse	48
	TNBS colitis	mouse	49
	normal	rat	41
	normal	dog	50
	normal	pig	51
	normal	monkey	52,53
	normal	human	44,47,54,55
	carcinoma	human	54-56
Rectum	carcinoma	human	54-56

H_4R= H_4 receptor; GI= Gastrointestinal; TNBS= Trinitrobenzene Sulphonic Acid

Table 1: Expression of histamine H_4Rs in the GI tract

GI EFFECTS OF H_4R LIGANDS

The functional data reported in intact animals with the available H_4R antagonists are summarized in Table 2.[35]

Pathological condition	Species	Ref.
Indomethacin-induced gastric damage	rat, mouse	57,58
TNBS-induced colitis	rat	59-61
Zymosan-induced peritonitis	mouse	19,21,24,62-64
Radiation-induced intestinal damage	rat	65
Ischemia-induced intestinal damage	rat	66
TNBS-induced visceral hypersensitivity	rat	67

H_4R= H_4 receptor; GI= Gastrointestinal; TNBS= Trinitrobenzene Sulphonic Acid

Table 2: Protective effects of histamine H_4R antagonists in the GI tract

In rodents the reference H_4R antagonist JNJ7777120 was unable to damage the gastric mucosa per se, even at the highest anti-inflammatory doses and, actually, it was able to reduce the gastric damage induced by indomethacin[57,58] in two models which are widely used to unravel either gastric damage or protection.[13] The gastroprotection induced by H_4R blockade was unrelated to antisecretory effects or alteration in GI motility;[35] moreover, it was found to differ from that induced by activation of H_3Rs, since it was not evidenced against necrotizing agents, such as concentrated acid.[68] Indeed, the extensive damage induced by concentrated acid (>0.35 N) is only prevented by "true" cytoprotective drugs,

ISSN 2377-8369 Open Journal http://dx.doi.org/10.17140/GOJ-1-103

like prostaglandins[14] or by mechanisms activating cellular defense, such as re-epithelization and cell proliferation.[69] It is thus more plausible to hypothesize a selective interference of H_4R antagonists in the widely recognized mechanism underlying NSAID-induced gastric damage, i.e. accumulation and activation of neutrophils in the gastric microvasculature.[70] In line with this, in several experimental models of intestinal damage, H_4R antagonists were able to reduce neutrophil infiltration in intestinal mucosa.[19,21,24,62-64]

The gastric safety of H_4R antagonists could be of major interest, when considering that the available anti-inflammatory drugs are still endowed with gastric toxicity;[14] nevertheless, the precise role of H_4R in the gastric mucosa remains to be proven, since data with selective ligands are intriguing: the H_4R agonist VUF8430[28] was paradoxically as effective as the antagonist JNJ7777120 in reducing indomethacin-induced lesions in the rat.[57]

The protective effect reported by Varga et al.[59] in a model of acute colitis induced by Trinitrobenzene Sulphonic Acid (TNBS) seems deemed of interest, when considering that this model resembles the human Crohn's disease under macroscopic, histopathological and immunological aspects.[71] In this assay, JNJ7777120 was able to reduce macroscopic damage, neutrophil infiltration and the production of both Tumor Necrosis Factor-alpha (TNF-α) and Interleukin-6 (IL-6), two cytokines that play a critical role in the pathogenesis of human disease.[59-60] Several groups have underlined the increase in histamine content in mucosal biopsies from Crohn's disease, Ulcerative Colitis (UC) and food allergy;[72-73] moreover, mast cells in colonic mucosal biopsies from IBS patients were found to release more histamine than in normal subjects.[73] The recent observation that histamine H_4Rs, together with H_1Rs, contribute to the postinflammatory visceral sensitivity in the TNBS-induced colitis assay,[67] leads to hypothesize that H_4R antagonists may be of therapeutic value in various pathological conditions with abdominal pain.

Finally, a possible role of histamine H_4Rs in cancer has been recently reviewed.[74] Recent studies have evidenced the presence of H_4Rs in gastric and colorectal tumor cells and a reduction of H_4R density has been observed, which parallels the cancer progression.[54,55,56] However, functional data with histamine and H_4R ligands are contradictory, with both stimulation and/or inhibition of cell proliferation and cell growth being observed.[74]

CONCLUSIONS

The protective effects displayed by some H_4R antagonists in a variety of experimental *in vivo* models suggest that histamine H_4R blockade is not deleterious for the GI tract and can actually activate gastric and intestinal mucosal defense mechanisms, at least in rodents. Despite these favourable premises, H_4R pharmacology is still intriguing and clinical studies are mandatory in order to assess the potential benefit of H_4R antagonists in human GI disease. A careful validation of experimental assays, ligand selectivity and antibody specificity is of key importance to unravel the location and functional role of H_4Rs in the GI tract, and the therapeutic value of drugs targeting this receptor in the human pathology.

ACKNOWLEDGEMENTS

The work is part of the EU FP7 COST Action BM0806: Recent advances in histamine receptor H_4R research.

REFERENCES

1. Black JW, Duncan WA, Durant CJ, Ganellin CR, Parsons EM. Definition and antagonism of histamine H2-receptors. *Nature*. 1972; 236: 385-390. doi: 10.1038/236385a0

2. Feldman M, Burton ME. Histamine2-receptor antagonists. Standard therapy for acid-peptic diseases. First part. *N Engl J Med*. 1990; 323: 1672-1680. doi: 10.1056/NEJM199012133232405

3. Feldman M, Burton ME. Histamine2-receptor antagonists. Standard therapy for acid-peptic diseases. Second part. *N Engl J Med*. 1990; 323: 1749-1755. doi: 10.1056/NEJM199012203232507

4. Arrang JM, Garbarg M, Schwartz JC. Auto-inhibition of brain histamine release mediated by a novel class (H3) of histamine receptors. *Nature.* 1983; 302: 832-837. doi: 10.1038/302832a0

5. Vohora D. The third Histamine Receptor: Selective Ligands as Potential Therapeutic Agents in CNS Disorders. Boca Raton, FL (USA); CRC Press, *Taylor and Francis Group*; 2008.

6. Leurs R, Chazot PL, Shenton FC, Lim HD, de Esch IJ. Molecular and biochemical pharmacology of the histamine H4 receptor. *Br J Pharmacol*. 2009; 157: 14-23. doi: 10.1111/j.1476-5381.2009.00250.x

7. Zampeli E, Tiligada E. The role of histamine H4 receptor in immune and inflammatory disorders. *Br J Pharmacol*. 2009; 157: 24-33. doi: 10.1111/j.1476-5381.2009.00151.x

8. Stark H. Histamine H4 receptor: a novel target in immunoregulation and inflammation. London, Great Britain; *Versita Ltd*; 2013.

9. Celanire S, Wijtmans M, Talaga P, Leurs R, de Esch IJ. Keynote review: histamine H3 receptor antagonists reach out for the clinic. *Drug Discov Today*. 2005; 10: 1613-1627. doi: 10.1016/S1359-6446(05)03625-1

10. Passani MB, Blandina P, Torrealba F. The histamine H3 receptor and eating behaviour. *J Pharmacol Exp Ther*. 2011; 336: 24-29. doi: 10.1124/jpet.110.171306

11. Thurmond RL, Gelfand EW, Dunford PJ. The role of histamine H1 and H4 receptors in allergic inflammation: the search for new antihistamines. *Nat Rev Drug Discov*. 2008; 7: 41-53. doi: 10.1038/nrd2465

12. Engelhardt H, Smits RA, Leurs R, Haaksma E, de Esch IJ. A new generation of anti-histamines: Histamine H4 receptor antagonists on their way to the clinic. *Curr Opin Drug Discov Devel*. 2009; 12: 628-643.

13. Wallace JL. Prostaglandins, NSAIDs, and gastric mucosal protection: why doesn't the stomach digest itself? *Physiol Rev*. 2008; 88: 1547-1565. doi: 10.1152/physrev.00004.2008

14. Wallace JL. COX-2: a pivotal enzyme in mucosal protection and resolution of inflammation. *Scientific World Journal*. 2006; 6: 577-588.doi: http://dx.doi.org/10.1100/tsw.2006.122

15. Whittle BJ. Mechanisms underlying intestinal injury induced by anti-inflammatory COX inhibitors. *Eur J Pharmacol*. 2004; 500: 427-439. doi: 10.1016/j.ejphar.2004.07.042

16. Wallace JL. Mechanisms, prevention and clinical implications of nonsteroidal anti-inflammatory drug-enteropathy. *World J Gastroenterol*. 2013; 19: 1861-1876. doi: 10.3748/wjg.v19.i12.1861

17. Zhang M, Thurmond RL, Dunford PJ. The histamine H4 receptor: a novel modulator of inflammatory and immune disorders. *Pharmacol Ther*. 2007; 113: 594-606. doi: 10.1016/j.pharmthera.2006.11.008

18. Strakhova MI, Cuff CA, Manelli AM, et al. In vitro and in vivo characterization of A-940894: a potent histamine H4 receptor antagonist with anti-inflammatory properties. *Br J Pharmacol*. 2009; 157: 44-54. doi: 10.1111/j.1476-5381.2009.00236.x

19. Takeshita K, Sakai K, Bacon KB, Gantner F. Critical role of histamine H4 receptor in leukotriene B4 production and mast cell-dependent neutrophil recruitment induced by zymosan in vivo. *J Pharmacol Exp Ther*. 2003; 307: 1072-1078. doi: 10.1124/jpet.103.057489

20. Bell JK, McQueen DS, Rees JL. Involvement of histamine H4 and H1 receptors in scratching induced by histamine receptor agonists in Balb C mice. *Br J Pharmacol*. 2004; 142: 374-380. doi: 10.1038/sj.bjp.0705754

21. Thurmond RL, Desai PJ, Dunford PJ, et al. A potent and selective histamine H4 receptor antagonist with anti-inflammatory properties. *J Pharmacol Exp Ther*. 2004; 309: 404-413. doi: 10.1124/jpet.103.061754

22. Coruzzi G, Adami M, Guaita E, de Esch IJ, Leurs R. Anti-inflammatory and antinociceptive effects of the selective histamine H4-receptor antagonists JNJ7777120 and VUF6002 in a rat model of carrageenan-induced acute inflammation. *Eur J Pharmacol*. 2007; 563: 240-244.doi: 10.1016/j.ejphar.2007.02.026

23. Ahmad SF, Zoheir KM, Abdel-Hamied HE, et al. The role of a histamine 4 receptor as an anti-inflammatory target in carrageenan-induced pleurisy in mice. *Immunology*. 2014; Jan 25. doi: 10.1111/imm.12257.

24. Hsieh GC, Chandran P, Salyers AK, et al. H4 receptor antagonism exhibits anti-nociceptive effects in inflammatory and neuropathic pain models in rats. *Pharmacol Biochem Behav*. 2010; 95: 41-50. doi: 10.1016/j.pbb.2009.12.004

25. de Esch IJ, Thurmond RL, Jongejan A, Leurs R. The histamine H4 receptor as a new therapeutic target for inflammation. *Trends Pharmacol Sci*. 2005; 26: 462-469. doi: http://dx.doi.org/10.1016/j.tips.2005.07.002

26. Jablonowski JA, Grice CA, Chai W, et al. The first potent and selective non-imidazole human histamine H4 receptor antagonists. *J Med Chem*. 2003; 46: 3957-3960. doi: 10.1021/jm0341047

27. Lim HD, van Rijn RM, Ling P, Bakker RA, Thurmond RL, Leurs R. Evaluation of histamine H1-, H2-, and H3-receptor ligands at the human histamine H4 receptor: identification of 4-methylhistamine as the first potent and selective H4 receptor agonist. *J Pharmacol Exp Ther*. 2005; 314: 1310-1321. doi: 10.1124/jpet.105.087965

28. Lim HD, Smits RA, Bakker RA, van Dam CM, de Esch IJ, Leurs R. Discovery of S-(2-guanidylethyl)-isothiourea (VUF 8430) as a potent nonimidazole H4 receptor agonist. *J Med Chem*. 2006; 49: 6650-6651. doi: 10.1021/jm060880d

29. Rosethorne EM, Charlton SJ. Agonist-biased signaling at the histamine H4 receptor: JNJ7777120 recruits β-arrestin without activating G proteins. *Mol Pharmacol*. 2011; 79: 749-757. doi: 10.1124/mol.110.068395

30. Seifert R, Schneider EH, Dove S, et al. Paradoxical stimulatory effects of the "standard" histamine H4-receptor antagonist JNJ7777120: the H4 receptor joins the club of 7 transmembrane domain receptors exhibiting functional selectivity. *Mol Pharmacol*. 2011; 79: 631-638. doi: 10.1124/mol.111.071266

31. Neumann D, Beermann S, Seifert R. Does the histamine H4 receptor have a pro- or anti-inflammatory role in murine bronchial asthma? *Pharmacology*. 2010; 85: 217-223. doi: 10.1159/000285088

32. Adachi N, Liu K, Motoki A, Nishibori M, Arai T. Suppression of ischemia/reperfusion liver injury by histamine H4 receptor stimulation in rats. *Eur J Pharmacol*. 2006; 544: 181-187. doi: 10.1016/j.ejphar.2006.06.053

33. Coruzzi G, Pozzoli C, Adami M, et al. Strain-dependent effects of the histamine H4 receptor antagonist JNJ7777120 in a murine model of acute skin inflammation. *Exp Dermatol*. 2012: 21: 32-37. doi: 10.1111/j.1600-0625.2011.01396.x

34. Schreeb A, Lazewska D, Dove S, Buschauer A, Kiec-Kononowicz K, Stark H. Histamine H4 receptor ligands. In: Stark H, ed. Histamine H4 receptor: a novel drug target in immunoregulation and inflammation. London, Great Britain: Versita Ltd; 2013: 21-61.

35. Coruzzi G, Adami M, Pozzoli C. Role of histamine H4 receptors in the gastrointestinal tract. *Front Biosci*. 2012; 4: 226-239.

36. Yu S, Stahl E, Li Q, Ouyang A. Antigen inhalation induces mast cells and eosinophils infiltration in the guinea pig esophageal epithelium involving histamine-mediated pathway. *Life Sci*. 2008; 82: 324-330. doi: 10.1016/j.lfs.2007.12.002

37. Morini G, Becchi G, Shenton FC, Chazot PL, Grandi D. Histamine H3 and H4 receptors are expressed on distinct endocrine cell types in the rat fundic mucosa. *Inflamm Res*. 2008; 57(Suppl. 1): S57-S58. doi: 10.1007/s00011-007-0628-9

38. Liu C, Ma X, Jiang X, Wilson SJ, Hofstra CL, Blevitt J. Cloning and pharmacological characterization of a fourth histamine receptor (H4) expressed in bone marrow. *Mol Pharmacol*. 2001; 59: 420-426. doi: 10.1124/mol.59.3.420

39. Zhang C, Xiong Y, Li J, et al. Deletion and down-regulation of HRH4 gene in gastric carcinomas: a potential correlation with tumor progression. *PLoS One*. 2012; 7: e31207. doi: 10.1371/journal.pone.0031207

40. Takagaki K, Osawa S, Horio Y, et al. Cytokine responses of intraepithelial lymphocytes are regulated by histamine H2 receptor. *J Gastroenterol*. 2009; 44: 285-296. doi: 10.1007/s00535-009-0019-9

41. Chazot PL, Shenton FC, Waldvogel H, Grandi D, Morini G. The H4 histamine receptor is expressed in both the human CNS and rodent PNS. In: European Histamine Research Society, 36th Annual Meeting, Florence (Italy), May 9-12th, 2007: 27.

42. Jiang W, Lim HD, Zhang M, et al. Cloning and pharmacological characterization of the dog histamine H4 receptor. *Eur J Pharmacol*. 2008; 592: 26-32. doi: 10.1016/j.ejphar.2008.06.095

43. Nakamura T, Itadani H, Hidaka Y, Ohta M, Tanaka K. Molecular cloning and characterization of a new human histamine receptor, HH4R. *Biochem Biophys Res Commun*. 2000; 279: 615-620.doi: 10.1006/bbrc.2000.4008

44. Oda T, Morikawa N, Saito Y, Masuho Y, Matsumoto S. Molecular cloning and characterization of a novel type of histamine receptor preferentially expressed in leukocytes. *J Biol Chem*. 2000; 275: 36781-36786. doi: 10.1074/jbc.M006480200

45. Cogè F, Guenin SP, Rique H, Boutin JA, Galizzi JP. Structure and expression of the human histamine H4-receptor gene. *Biochem Biophys Res Commun*. 2001; 284: 301-309. doi: 10.1006/bbrc.2001.4976

46. Morse KL, Behan J, Laz TM, et al. Cloning and characterization of a novel human histamine receptor. *J Pharmacol Exp Ther*. 2001; 296: 1058-1066.

47. Sander LE, Lorentz A, Sellge G, et al. Selective expression of histamine receptors H1R, H2R, and H4R, but not H3R, in the human intestinal tract. *Gut*. 2006; 55: 498-504.

48. Kumawat AK, Gotlind YY, Fredin MF, Willen R, Strid H, Hultgren-Hornquist E. Expression patterns of histamine receptors in the Gαi2-deficient mouse model of colitis. *Inflamm Res*. 2010; 59(Suppl. 4): S358-S359.

49. Sutton TL, Zhao A, Madden KB, et al. Antiinflammatory mechanisms of enteric Heligmosomoides polygyrus infection against trinitrobenzene sulfonic acid-induced colitis in a murine model. *Infect Immun*. 2008; 76: 4772-4782. doi: 10.1128/IAI.00744-07

50. Eisenschenk MNC, Torres SM, Oliveira S, Been CS. The expression of histamine H4 receptor mRNA in the skin and other tissues of normal dogs. *Vet Dermatol*. 2011; 22: 396-400. doi: 10.1111/j.1365-3164.2011.00959.x

51. Oda T, Matsumoto S, Masuho Y, et al. cDNA cloning and characterization of porcine histamine H4 receptor. *Biochim Biophys Acta*. 2002; 1575: 135-138. doi: 10.1016/S0167-4781-(02)00236-1

52. Oda T, Matsumoto S, Matsumoto M, et al. Molecular cloning of monkey histamine H4 receptor. *J Pharmacol Sci*. 2005; 98: 319-322. doi: 10.1254/jphs.SC0050033

53. Kim H, Dwyer L, Song JH, et al. Identification of histamine receptors and effects of histamine on murine and simian colonic excitability. *Neurogastroenterol Motil*. 2011; 23: e949-e409. doi: 10.1254/jphs.SC0050033

54. Cianchi F, Cortesini C, Schiavone NF, et al. The role of cyclooxygenase-2 in mediating the effects of histamine on cell proliferation and vascular endothelial growth factor production in colorectal cancer. *Clin Cancer Res*. 2005; 11: 6807-6815. doi: 10.1158/1078-0432.CCR-05-0675

55. Boer K, Helinger E, Helinger A, et al. Decreased expression of histamine H1 and H4 receptors suggests disturbance of local regulation in human colorectal tumours by histamine. *Eur J Cell Biol*. 2008; 87: 227-236. doi: 10.1016/j.ejcb.2007.12.003

56. Fang Z, Yao W, Xiong Y, et al. Attenuated expression of HRH4 in colorectal carcinomas: a potential influence on tumor growth and progression. *BMC Cancer*. 2011; 11: 195-205. doi: 10.1186/1471-2407-11-195

57. Coruzzi G, Adami M, Pozzoli C, Smits R, de Esch IJP, Leurs R. Gastroprotective effects of histamine H4 receptor li gands in rodent ulcer models. *Br J Pharmacol*. 2010; 7: 150P.

58. Adami M, Pozzoli C, Menozzi A, et al. Effects of histamine H4 receptor ligands in a mouse model of gastric ulceration. *Pharmacology*. 2012; 89: 287-294.doi: 10.1159/000337736

59. Varga C, Horvath K, Berko A, Thurmond RL, Dunford PJ, Whittle BJ. Inhibitory effects of histamine H4 receptor antagonists on experimental colitis in the rat. *Eur J Pharmacol*. 2005; 522: 130-138. doi: 10.1016/j.ejphar.2005.08.045

60. Dunford PJ, Varga, C, Thurmond RL, Whittle BJ. Histamine H4 receptor antagonism attenuates toll-like receptor signaling and inhibits experimental colitis in the rat. *Gastroenterology*. 2006; 130: A-689.

61. Fogel WA, Jochem J, Lewinski A. Influence of the H3/H4 receptor antagonist, thioperamide on regional haemodinamics in rats with trinitrobenzene sulfonic acid-induced colitis. *Inflamm Res*. 2007; 56 (Suppl. 1): S21-S22. doi: 10.1007/s00011-006-0510-1

62. Cowart MD, Altenbach RJ, Liu H, et al. Rotationally constrained 2,4-diamino-5,6-disubstituted pyrimidines: a new class of histamine H4 receptor antagonists with improved druglikeness and in vivo efficacy in pain and inflammation models. *J Med Chem*. 2008; 51: 6547-6557. doi: 10.1021/jm800670r

63. Liu H, Altenbach RJ, Carr TL, et al. cis-4-(Piperazin-1-yl)-5,6,7a,8,9,10,11,11a-octahydrobenzofuro[2,3-h]quinazolin-2-amine (A-987306), a new histamine H4R antagonist that blocks pain responses against carrageenan-induced hyperalgesia. *J Med Chem*. 2008; 51: 7094-7098. doi: 10.1021/jm8007618

64. Strakhova MI, Cuff CA, Manelli AM, et al. In vitro and in vivo characterization of A-940894: a potent histamine H4 receptor antagonist with anti-inflammatory properties. *Br J Pharmacol*. 2009; 157: 44-54. doi: 10.1111/j.1476-5381.2009.00236.x

65. Medina V, Cricco G, Mohamad N, et al. Histamine is a selective protector against cellular damage produced by ionizing radiation. *Inflamm Res*. 2005; 54(Suppl. 1): S17-S18. doi: 10.1007/s00011-004-0407-9

66. Ghizzardi P, Gobbetti T, Bertoni S, et al. Histamine H4 receptor antagonism and mesenteric ischemia/reperfusion injury in mice. *Gastroenterology*. 2009; 136 (Suppl. 1): A-397. doi: http://dx.doi.org/10.1016/s0016-5085(09)61826-6

67. Deiteren A, De Man JG, Ruyssers NE, Moreels TG, Pelckmans PA, De Winter BY. Histamine H4 and H1 receptors contribute to postinflammatory visceral hypersensitivity. *Gut*. 2014; Feb 21. doi: 10.1136/gutjnl-2013-305870.

68. Coruzzi G, Adami M, Pozzoli C, de Esch IJ, Smits R, Leurs R. Selective histamine H3 and H4 receptor agonists exert opposite effects against the gastric lesions induced byHCl in the rat stomach. *Eur J Pharmacol*. 2011; 669: 121-127. doi: 10.1016/j.ejphar.2011.07.038

69. Coruzzi G, Adami M. Peripheral actions and therapeutic potential in periphery. In: Vohora D, ed. The third Histamine Receptor: Selective Ligands as Potential Therapeutic Agents in CNS Disorders. New York, NY, USA: CRC Press, Taylor and Francis Group; 2008: 167-209.

70. Wallace JL, Keenan CM, Granger DN. Gastric ulceration induced by nonsteroidal anti-inflammatory drugs is a neutrophil-dependent process. *Am J Physiol*. 1990; 259: G462-G467.

71. Elson CO, Sartor RB, Tennyson GS, Riddell RH. Experimental models of inflammatory bowel disease. *Gastroenterology*. 1995; 109: 1344-1367. doi: http://dx.doi.org/10.1016/0016-5085(95)90599-5

72. Raithel M, Matek M, Baenkler HW, Jorde W, Hahn EG. Mucosal histamine content and histamine secretion in Crohn's disease, ulcerative colitis and allergy enteropathy. *Int Arch Allergy Immunol*. 1995; 108: 127-133.

73. Barbara G, Stanghellini V, De Giorgio R, et al. Activated mast cells in proximity to colonic nerves correlate with abdominal pain in irritable bowel syndrome. *Gastroenterology*. 2004; 126: 693-702.doi: http://dx.doi.org/10.1053/j.gastro.2003.11.055

74. Medina VA, Coruzzi G, Martinal Lamas DJ, et al. Histamine in cancer. In: Stark H ed. Histamine H4 receptor: a novel drug target in immunoregulation and inflammation. London, Great Britain, *Versita Ltd*. 2013; 259-308.

GASTRO

Openventio PUBLISHERS

ISSN 2377-8369 Open Journal http://dx.doi.org/10.17140/GOJ-1-104

Case Report

*Corresponding author:
Simone Sala, MD
Department of Radiology
University of Ferrara
via Savonarola, 9
44121 Ferrara FE, Italy
Tel. +390532212146
E-mail: dott.sala@gmail.com

Volume 1 : Issue 1
Article Ref. #: 1000GOJ1104

Article History:
Received: October 15th, 2014
Accepted: January 14th, 2015
Published: January 19th, 2015

Citation:
Sala S, Raimondi E, Bassi M, Bernardoni A, Rizzati R, Benea G. Gastric diverticulum misdiagnosed as a left adrenal lesion. *Gastro Open J.* 2015; 1(1): 13-14.

Gastric Diverticulum Misdiagnosed as a Left Adrenal Lesion

Simone Sala[1*], E. Raimondi[2], M. Bassi[2], A. Bernardoni[2], R. Rizzati[1] and G. Benea[1]

[1]S. Anna Hospital, Department of Diagnostic and Interventional Radiology, Ferrara, Italy

[2]Department of Radiology and Medical Imaging, University of Ferrara, Ferrara, Italy

CASE REPORT

We report a case of gastric diverticulum misdiagnosed as a left adrenal lesion on both ultrasound and CT imaging and later identified on a follow-up CT.

A 56 year-old man with a history of gastroesophageal reflux disease was admitted to our Hospital with left abdominal pain. There was no history of vomiting, hematemesis, melena, tiredness or jaundice. Bowel sounds were normal and no masses were identified at clinical examination. An ultrasound abdominal scan was performed and a hypoechoic 24 mm mass in left adrenal loggia was reported. An abdominal CT scan showed a 2.4 cm rounded mass in the area of the left adrenal gland with densitometric mean values of -7 HU, interpreted as adrenal adenoma (Figure 1). In the following days the patient underwent a complete endocrinological evaluation that showed normal findings with normal adrenal function; ACTH level and urinary catecholamines were both within normal range. The patient was then discharged and scheduled for a follow-up CT.

After 6 months the patient underwent a second follow-up CT that showed a little intralesional gas bubble (Figure 2); CT scan was subsequently repeated after oral administration of contrast medium (Gastrografin®); the previously described lesion showed continuity with the gastric wall, contrast medium staining of the lumen lesion with contextual air bubbles suggestive of gastric diverticulum (Figure 3 and 4). Diagnosis was later confirmed by esophagogastroduodenoscopy.

Figure 1: Axial contrast- enhanced CT image showing a rounded lesion interpreted as the upper portion of the left adrenal gland with sharp edges and weak parietal enhancement.

Figure 2: Axial contrast- enhanced CT image showing a gas bubble in the ventral aspect of the suprarenal lesion.

ISSN 2377-8369 Open Journal http://dx.doi.org/10.17140/GOJ-1-104

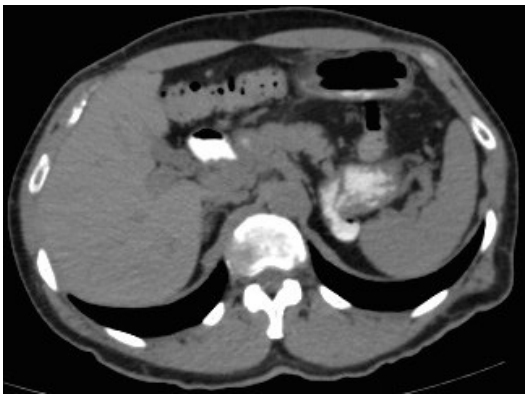

Figure 3: Axial non-enhanced ct image showing an intense lumen staining of both the lesion and the gastric lumen after oral administration of contrast medium.

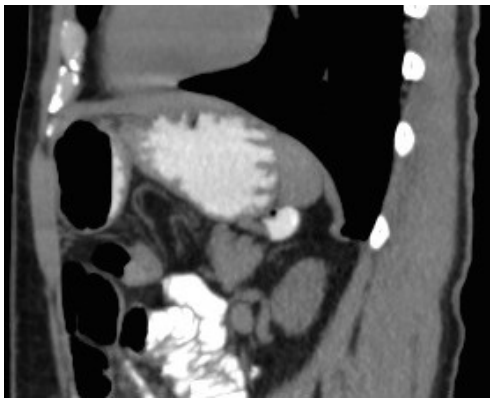

Figure 4: Sagittal reconstruction of the same follow-up ct scan (shown in figure 3) after oral administration of contrast medium.

DISCUSSION

Gastric Diverticulum (GD) is an outpouching of the gastric wall. GDs are rare and they are commonly incidentally detected during diagnostic examinations of the abdomen. Prevalence ranges from 0.04% in upper gastrointestinal tract X-ray examination to 0.01%-0.11% at esophagogastroduodenoscopy.[1]

GDs are the least common diverticula of the gastrointestinal tract. Two main categories are identified, congenital and acquired. Diverticula of the gastric antrum, prepyloric or pyloric regions are extremely rare and usually asymptomatic. Clinical history may vary from complete absence of symptoms to dyspepsia, to major upper Gastrointestinal (GI) bleeding, making this condition a diagnostic challenge.[2]

Masses mimicking adrenal tumors appear more frequently on the left side due to the close proximity of the left adrenal gland to different structures such as the gastric fundus, the first loops of the jejunum, the spleen, the pancreas and the left kidney.[3] Conditions such as gastric stasis, gastric diverticulum, duplicated bowel loop, accessory spleen, splenic vessels, aneurysm of the splenic artery, portosystemic venous collaterals (in portal hypertension), left renal and pancreatic tumors and submucosal gastric tumor may be difficult to differentiate from left adrenal tumor.[4,5]

In order to prevent false diagnosis of adrenal tumor on CT, the adrenal region should be scanned with thin slices performed with multirow detector CT with the support of multiplanar reconstruction images. In the case of suspected gastric diverticula, oral administration of contrast medium may be indicated.

In conclusion, on the basis of our experience, the possibility of gastric diverticulum should be taken into consideration in the full differential diagnosis of adrenal masses.

CONFLICTS OF INTERESTS

We declare there are neither conflicts of interest nor acknowledgements'.

CONSENT

No consent is required to our article publication.

REFERENCES

1. Simstein NL. Congenital gastric anomalies. *Am Surg*. 1986; 52: 264-268.

2. Diverticula in the digestive tract and their complications. *Klin Med (Mosk)*. 2011; 89(5): 9-16.

3. Rashid F, Aber A, Iftikhar SY. A review on gastric diverticulum. *World Journal of Emergency Surgery.* 2012, 7: 1. doi: 10.1186/1749-7922-7-1

4. Francis IR, Gross MD, Shapiro B, Korobkin M, Quint LE. Integrated imaging of adrenal disease. *Radiology*.1992; 184: 1-13. doi: http://dx.doi.org/10.1148/radiology.184.1.1609063

5. Verbeeck N, De Geeter TD. Suprarenal mass due to a gastric diverticulum. *J Belge Radiol*. 1994; 77: 119-120.

GASTRO

Openventio PUBLISHERS

ISSN 2377-8369 Open Journal http://dx.doi.org/10.17140/GOJ-1-105

Research

*Corresponding author:
Yao Fong, MD
Director
General Thoracic Surgery Program
Department of Surgery
Divisions of Cardiovascular and Thoracic Surgery
Chi-Mei Medical Center
No. 901, Zhonghua Road
Tainan, 710, Taiwan
Tel. +886(919) 635-312
Fax: +886(6) 281-4813
E-mail: fongyao760719@gmail.com; bkducky@gmail.com

Volume 1 : Issue 1
Article Ref. #: 1000GOJ1105

Article History:
Received: December 15th, 2014
Accepted: February 11th, 2015
Published: February 12th, 2015

Citation:
Su Y-C, Fong Y, Chen J-K, Lin H-C. Robot-assisted minimally invasive McKeown esophagectomy with a four-arm platform: technique and early experience. *Gastro Open J.* 2015; 1(1): 15-22.

Robot-Assisted Minimally Invasive McKeown Esophagectomy with a Four-Arm Platform: Technique and Early Experience

Ying-Chieh Su[1,2], Yao Fong[1*], Jhao-Kun Chen[1] and Hsiang-Chen Lin[3]

[1]*Department of Surgery, Divisions of Cardiovascular and Thoracic Surgery, Chi-Mei Medical Center, Tainan, Taiwan*

[2]*Photonic Systems Institute, National Chiao Tung University, Tainan, Taiwan*

[3]*Department of Surgery, Divisions of General Surgery, Chi-Mei Medical Center, Tainan, Taiwan*

ABSTRACT

Objectives: We report an early, single-institution experience of Robot-Assisted Minimally Invasive McKeown Esophagectomy (RAMIME) using a four-arm platform. The technique details, rationale, complications, and pitfalls during procedure development are discussed.
Methods: This was a retrospective observational study.
Results: Nine of the 11 patients (median age: 57 years [range: 45-83]) had a complete (R0) resection; 10 were given induction treatment combined with chemoradiation. The median operative time was 795 min (range: 635-975). The median thoracoscopic console time was 270 min (range: 135-330). The median laparoscopic console time was 160 min (range: 150-260 min). The median blood loss was 300 cm^3 (range: 100-650), and the median length of hospital stay was 18 days (range: 14-36). The median number of lymph nodes harvested was 28 (range: 9-39). No patients were converted to open procedures. Four patients had major complications; one died of liver failure on postoperative day 16; and none had clinically significant anastomotic leaks.
Conclusions: RAMIME is feasible. With good understanding of the robotic concepts and a good robotic team, RAMIME is worth trying. In addition to its well-known benefits, RAMIME permits replacing one human assistant.

KEYWORDS: Esophageal cancer; Esophageal surgery; Minimally invasive surgery; McKeown; Robot; Surgery/incisions/exposures/techniques.

INTRODUCTION

Minimally Invasive Esophagectomy (MIE) is becoming a standard surgical method for treating esophageal cancer in Asia. Its outcomes are comparable to those of open surgery. Furthermore, MIE has fewer pulmonary complications and less pain.[1,2]

The da Vinci robotic surgical system (Intuitive Surgical, Sunnyvale, CA, USA) was granted United States Food and Drug Administration approval in July 2000; robotic techniques are increasingly being adopted in America for many types of laparoscopic surgery. The benefits of a robotic approach are three-dimensional vision; camera stability; instruments with a high degree of dexterity, precision, and control; and a 3rd arm for self-assistance.

Studies[3,4] have described a robotic approach to esophageal surgery when treating achalasia and hiatal hernia; however, experience with Robot-Assisted MIE (RAMIE) is

ISSN 2377-8369 Open Journal http://dx.doi.org/10.17140/GOJ-1-105

still limited. Several series[5-10] have reported variable hybrid approaches for RAMIE, but only two[11,12] describe its surgical details and outcomes.

We report our first experience of complete RAMIE with a four-arm robotic platform, and describe technical modifications made to overcome specific challenges. Short-term surgical outcomes and complications encountered are discussed.

PATIENTS AND METHODS

Patient Selection

We enrolled 11 patients with esophageal cancer. All had undergone a RAMIME using a combined thoracoscopic and laparoscopic approach. All patients underwent preoperative staging and evaluation, which included a medical history and physical examination, an upper gastrointestinal endoscopy and biopsy, a bone scan, computed tomography of the chest, and abdominal and endoscopic ultrasound evaluations. Patients with T2 tumors or greater, or nodal involvement, or both, were referred for induction chemoradiation therapy. A waiver of informed consent for retrospective studies was granted by our institutional review board.

All 11 operations were performed by the same two attending thoracic surgeons with advanced experience in MIE (YCS, YF). Most of the operations were assisted by nursing and anesthesiology staff experienced in non-robotic minimally invasive esophageal resections.

Data Collection

Patient demographic characteristics, outcomes, and complications, graded in accordance with the Common Terminology Criteria for Adverse Events version 4.0,[13,14] were retrospectively collected by reviewing the patients' charts. Intraoperative data were obtained from the operative record.

Operation Technique: Thoracoscopic Phase

RAMIE and non-robotic MIE techniques from the Mayo Clinic and Memorial Sloan-Kettering Cancer Center (MSKCC) were used to modify previously published standardized techniques[11] and create the technique we used. Our team included 1 attending surgeon (YCS or YF) and an assistant (a fellow or resident) seated at the bedside. For the first few cases, we requested that our fellow (JKC), who is familiar with MIE procedures, be at the bedside. After the procedure had been standardized, and when the residents better understood it, rotating residents replaced JKC.

Patient Positioning and Port Placement

The patient was first placed in the standard left-lateral decubitus position. The table was then rotated leftward to put the patient into a semiprone position, which kept the operation field clear. The robot approached the patient about 45° dorsally from the cranial midline. Port placement, operating layout, and the robot-cart trajectory over the right shoulder are depicted in figure 1. A transparent laparoscopic port (Kii Fios First Entry; Applied Medical, Rancho Santa Margarita, CA, USA) was inserted using a video thoracoscopic guide at the anterior axillary line of the 6th Intercostal space (ICS) for the camera. This prevented the camera from colliding with the iliac crest. CO_2 insufflation was then begun at a pressure of 8 mmHg. The 2nd arm was put in the 8th ICS, the midaxillary line. The 3rd arm was put in the 10th ICS, the paraspinal space. It contributed to the lung retraction and reduced the assistant's work. The 1st arm was put in the 4th ICS, the anterior axillary line. A 12 mm assistant port was placed at the site of the diaphragmatic insertion, the anterior axillary line, between the camera and the 2nd arm. The robotic camera was introduced facing 30° downward.

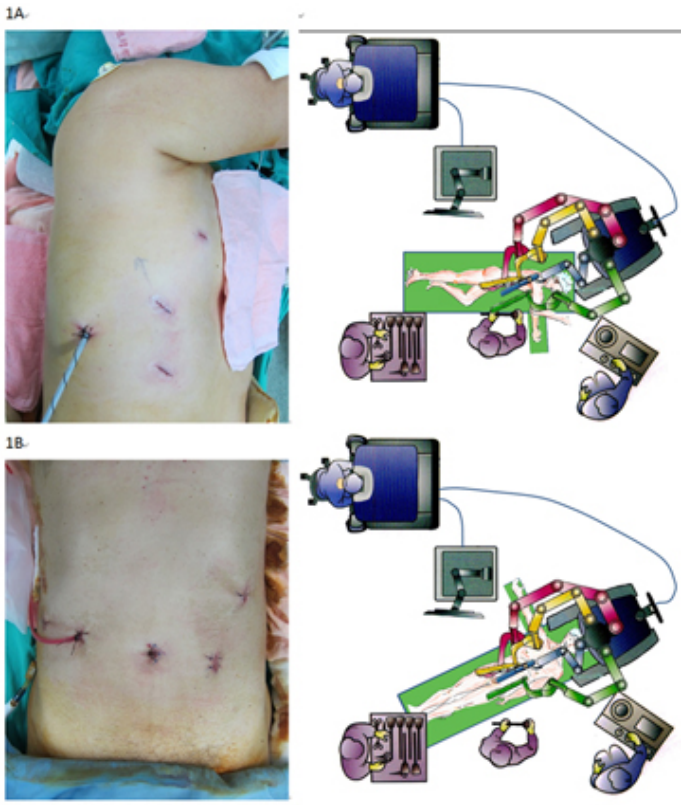

Figure 1: (A) Thoracoscopic phase room setup and port placement; (B) laparoscopic phase room setup and port placement.

Esophageal Mobilization

The important steps of the thoracoscopic phase are illustrated in figure 2. An ultrasound shears (Harmonic Scalpel; Ethicon, Cincinnati, OH, USA) or unipolar spatula was used in the 1st robotic arm; a bipolar fenestrate grasp was used in the 2nd arm; and a double fenestrate grasp was used in the 3rd arm for lung retraction. Dissection was begun at the level of the inferior pulmonary vein and then continued ventral to the esophagus along the pericardium to the left pleura (Figure 2A) and dorsal to the esophagus along the spine and aorta to the left pleura. When the thoracic duct was found midway, it was ligated using a ligation

ISSN 2377-8369 Open Journal http://dx.doi.org/10.17140/GOJ-1-105

system (Hem-o-lok; Teleflex, Research Triangle Park, NC, USA). When the dissections conjoined at the contralateral side, the esophagus was retracted with the 3rd arm (Figure 2B). Then the instruments in the 1st and 2nd robotic arms were exchanged. A tension plane was created and transected using the 2nd-arm energy-instrument (Figure 2C). The subcarinal lymph nodes were removed in this manner. Then the azygos vein was looped and transected with an endocutter (Echelon; Ethicon, Cincinnati, OH, USA) (Figure 2D). The posterior stump can be sutured to the chest wall for a better view. The right bronchial artery and vagus nerve were transected at this level. The left pleura and aortic arch were reached as a left boundary (Figure 2E). The dissection could easily exceed the thoracic inlet. Recurrent laryngeal nerve injury should be avoided here. Because the harmonic scalpel is usually too short here, the instruments in 1st and 2nd robotic-arm were exchanged. When the cranial part was finished, we turned to the hiatal region (Figure 2F). After a circular dissection of the hiatus, the cardia portion of the stomach was visible.

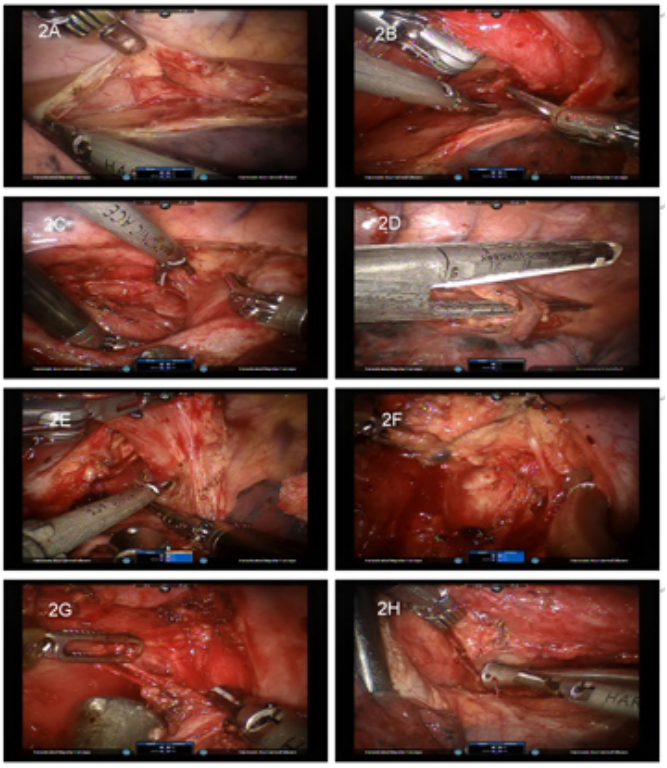

Figure 2: Thoracoscopic phase procedures.

Lymph Node Dissection

The inferior pulmonary ligament and subcarinal lymph node were removed during the esophageal dissection. When dealing the paratracheal lymph nodes, the 3rd arm was useful for retraction. When dissecting between the vagus nerve and superior vena cava, the medial side of the aorta could be reached. Take care not to injure the left recurrent laryngeal nerve (Figure 2G). Dissecting cranially between the trachea and vagus nerve cranially led us to the right recurrent laryngeal nerve (Figure 2H).

Operation Technique: Laparoscopic Phase

Patient positioning and port placement

Patients were placed supine on the operating table, with their right arms abducted at about 60°. Their left arms were adducted for an easier cervical approach. The table was turned to reverse Trendelenburg position to allow the intestine to move caudally. The cervical approach was used first because it is difficult to do so when the robot is docked. The esophagus was looped and hung with a rubber tube for later use.

The robot approached directly over the patient from the midline. Port placement, operating layout, and robotic cart trajectory are shown in figure 1. The camera port was made at the umbilicus. To enter the peritoneal cavity the open method was used, and then a balloon port (Kii Balloon Blunt Tip; Applied Med, Rancho Santa Margarita, CA, USA) to control air leaks. The peritoneum was distended using standard CO_2 insufflation. A standard 10 mm, 0° laparoscope was used for the initial inspection. The other ports' positions were determined using the camera rather than marks on the skin. A right-lateral, subcostal port for the 3rd arm was first placed just above the intestinal plane. A mid-clavicular port for the 2nd arm located midway between the camera port and the 3rd arm port was then made. A left-lateral subcostal port for the 1st arm was made. Finally, a left mid-clavicular 12 mm port was made for the assistant. This port was about 3-5 cm caudal to the umbilicus to avoid collision with the camera arm. If the patient has a previously made feeding jejunostomy, this port is placed lateral to the feeding jejunostomy stoma.

The important steps of the laparoscopic phase are illustrated in figure 3. After docking, we began the liver retraction. A needle driver was used in the 1st arm, a bipolar fenestrate grasp in the 2nd arm, and a double fenestrate grasp in the 3rd arm. A handmade liver retractor[14] was inserted into the peritoneal cavity. A straight needle was used to puncture at 2cm from the liver boarder to the abdominal wall around the xyphoid region (Figure 3A). Use the straight needle to bring the strings outside peritoneum and hang up a segment of JP (Jackson-Pratt) drain as a liver retractor. Two liver retractors were used to afford enough retraction force (Figure 3B). The strings were then pulled to hang up the liver with adequate tension.

Greater curvature mobilization

A 30° downward scope was used. A bipolar fenestrate grasp was in the 1st arm and ultrasound shears in the 2nd arm. The double fenestrate grasp in the 3rd arm was of great help for retracting the stomach. At first, the lesser sac was entered by dissecting the omentum. The dissection was performed 2 cm away from the right gastroepiploic artery to prevent an incidental thermal injury. When we entered the lesser sac, we inserted the double fenestrate grasp into it and retracted the stomach together with the right gastroepiploic artery (Figure 3C). With this approach, we could do a safe dissection. When the left gastroepiploic artery was met, we exchanged the instruments

ISSN 2377-8369 Open Journal http://dx.doi.org/10.17140/GOJ-1-105

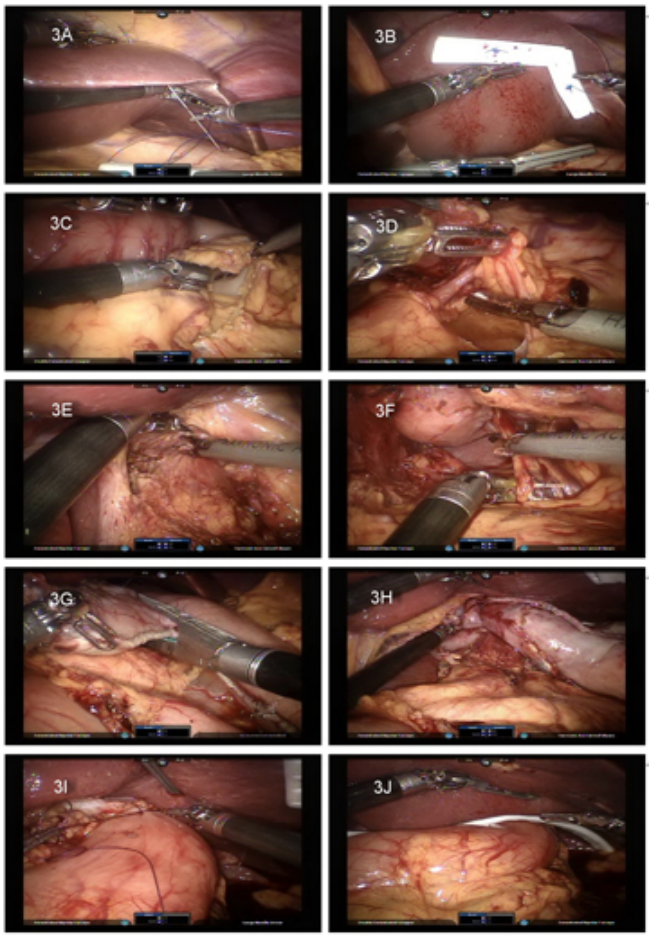

Figure 3: Laparoscopic phase procedures.

in the 1st and 2nd arms to promote short gastric artery dissection. The short gastric of the gastric fundus, however, was very difficult to approach without grasping. Therefore, we left the area and looked back to the pylorus portion. Using the 3rd arm to retract the stomach upward, the dissection of the pylorus portion was easily done.

Hiatal and retrogastric dissection

The left gastric vascular pedicle in the lesser curvature (Figure 3D) was found and transected with an endocutter. The hepatic trunk lymph node and hiatal crus dissections were performed (Figure 3E) with the 3rd arm retracted. After the hiatal dissection, it was easy to approach the short gastric arteries of the fundus portion *via* the lesser curvature (Figure 3F). We then finished the gastric mobilization.

Gastric tubularization

We introduced a new approach to form a gastric tube. To prepare for gastric tubularization, we used the 3rd arm to caudally retract the stomach *via* the lesser curvature. This approach elongated the stomach and opened the gastric rugae. We transected the lesser curvature mesentery at the junction of the right and left gastric arteries, and then transected the stomach with the endocutter to make a 3 cm wide tubular conduit (Figure 3G). When the endocutter approached the hiatus, we did not separate the hiatus and the conduit but simply left a 1 cm wide attachment there. Later, the lesser curvature could be pulled up together with the gastric tubular conduit (Figure 3H). To preclude the possibility of a blood supply compromise, we did not reinforce the sutures over the staple line; there was no leakage from this region.

Cervical anastomosis

By pulling the esophagus out *via* the cervical wound, the tubular gastric conduit and the remnant of the gastric cardia came out together. A correct axis was ensured with laparoscopic monitoring. A suture was made to prevent conduit torsion (Figure 3I). A JP drain was placed in the subhepatic region with the tip in the left subphrenic region *via* the 2nd arm port (Figure 3J). After the robot was undocked, the cervical anastomosis was made in a side-to-side pattern with the endocutter. The opening of the anastomosis was also closed with the endocutter. No pyloroplasty was performed, and no feeding jejunostomy was made in patients who had none preoperatively.

RESULTS

Demographic Characteristics

Eleven consecutive male patients underwent RAMIME between May 2012 and March 2013 (median age: 57 years; range: 45-83) (Table 1). Nine patients had squamous cell carcinoma, and 2 patients had adenosquamous cell carcinoma: 4 patients had cancer in the upper 1/3 of the esophagus, 5 in the middle 1/3, and 2 in the lower 1/3. A McKeown (three-field) approach was used for all patients, and 10 patients underwent neoadjuvant chemoradiation therapy.

Perioperative Outcomes

Median operative time (incision through wound closure, including docking and repositioning time) was 795 min (range: 635-975 min); Median thoracoscopic console time was 270 min (range: 135-330 min); and median laparoscopic console time was 160 min (range: 150-260 min). Ten patients had a complete macroscopic and microscopic (R0) resection. Median blood loss was 300 cm^3 (range: 100-650 cm^3); median number of lymph nodes harvested was 28 (range: 9-39); median hospital stay was 18 days (range: 14-36 days); median intense care unit stay was 3 days (range: 3-17 days); and median number of ventilation days was 1 (range: 1-17 days).

Conversions

No patients were converted to an open, non-robotic laparoscopic, or thoracoscopic approach.

Complications

Four patients had grade III or greater complications.

ISSN 2377-8369 Open Journal http://dx.doi.org/10.17140/GOJ-1-105

Variable	Number of Patients (%)
Age in Years [median (range)]	57 (45-83)
Gender (male)	11 (100)
Histological Result	
Squamous Cell Carcinoma	9 (92)
Adenocarcinoma	0 (0)
Adeno-Squamous Cell Carcinoma	2 (18)
Overall Stage, TN Clinical Stage	
Stage IIB	
T3N0	2 (19)
Stage IIIA	
T3N1	6 (53)
T3N2	2 (19)
Stage IV	
T3N0M1	1 (9)
Induction Therapy	
Chemotherapy and Radiation	10 (91)
Lymph Nodes Resected [median (range)]	28 (9-39)
Extent of Resection	
R0	10 (91)
R1	1 (9)
Length of Stay in Days [median (range)]	18 (14-36)

All data are given as number (%) unless otherwise indicated.
R0: gross and microscopic margins negative; R1: gross margin negative/microscopic margin positive.

Table 1: Patient demographics (n = 11) and data summary.

Two had pneumonitis and thus required a longer intubation time. One had an infection related to an implantable venous access device (Port-a-Cath): when antibiotic treatment was stopped, the patient had a fluctuating fever that subsided after the device was removed. Finally, one patient died of hepatic failure secondary to liver cirrhosis on postoperative day 16. The most common complication was pneumonitis (5 patients). The rate of grade II or greater anastomotic leak was 0% (Table 2).

DISCUSSION

MIE has been popular in Asia for the past decade, and reports[1,2] indicate that its popularity is increasing worldwide as well. To a lesser extent, hybrid RAMIE approaches, usually thoracoscopic, have also become popular. The advantages of the robotic approach-three-dimensional vision, camera stability, and instruments with a high degree of freedom have been emphasized.[5,7,10,11]

There are only two other published reports of complete RAMIEs using a combined thoracoscopic and laparoscopic approach. In 2007, Kernstine et al.[11] reported 8 complete RAMIMEs with a three-arm platform and 6 hybrid RAMIMEs. The thoracoscopic portions were done in a prone position. In

Grade, Complication	Number of Patients
Grade I	
Anastomotic Leak	1
Delayed Gastric Emptying	2
Chylothorax	1
Grade II	
Atrial Fibrillation	1
Pneumonitis	3
Wound Infection	1
Chylothorax	1
Recurrent Laryngeal Nerve Palsy	1
Grade III	
Pneumonitis	2
Catheter Related infection	1
Grade V	
Hepatic Failure	1

Table 2: Patient complications by Common Terminology Criteria for Adverse Events version 4.0.

the complete RAMIME group, there was one conversion to a thoracotomy. The median operative time was 672 min (range: 570-780 min). The incidence of major morbidity was 29%: 2 anastomotic leaks, 1 thoracic duct leak, and 2 cases of vocal cord paralysis. One patient with persistent aspiration pneumonia died 90 days post-surgery.

In 2013, Sarkaria et al.[12] reported the first series of complete RAMIEs with a four-arm robotic platform. Seventeen Ivor Lewis RAMIEs and 4 RAMIMEs have been reported. A left lateral decubitus position was used in the procedure. In contrast to Kernstine et al.[11] Sarkaria et al. used the prone position, which, although it has some advantages in lung retraction and requires clearing blood from the surgical field, also presents difficulties when it is necessary to convert to an open procedure. Five (24%) of 21 patients were converted to laparoscopic or thoracoscopic approaches. Another 5 were converted to open surgery. The median operative time was 556 min (range: 395-626 min) the incidence of major morbidity was 24%, including anastomotic leak (3 patients: 14%), respiratory failure (2 patients: 10%), pulmonary embolism (2 patients), and vocal cord paralysis (1 patient: 5%). One patient with respiratory failure secondary to anastomotic leak and tracheobronchial fistula died 70 days post-surgery.

The present study is the first reported series of RAMIMEs using a four-arm robotic platform and a modified semi-prone position. The procedure was developed and modified from the minimal invasive McKeown esophagectomy we have regularly performed for the past 7 years. One key difference between the prone and the left lateral decubitus positions is the facility of the 3rd robotic arm. In the prone position, there is not enough room to use a 3rd robotic arm. Although we can rely in

ISSN 2377-8369 Open Journal http://dx.doi.org/10.17140/GOJ-1-105

part on gravity to allow us to retract the lung, the 3rd robotic arm in the left lateral decubitus position offers better retraction force and dramatically decreases the assistant's work. Because of this, we placed the patient in the left lateral decubitus position to get enough space for the 3rd arm. Then the operation table was rotated leftward to create a semi-prone position. With this modification, we had enough room to dock the 3rd robotic arm and still use gravity to aid the lung retraction.

The extent of the lymphadenectomy and the rate of complete resection were comparable to those in Kernstine et al.[11] and Sarkaria et al.[12] both for open surgery and for MIEs. No patient had positive microscopic margins (R1) on the transection edge. Although a pathologist said that there were positive radial margins in 2 patients, the attending surgeons thought there was such a margin in only 1 patient: we found a pleural metastasis in one patient and resected that lesion with a clear safe margin.

We found an overall incidence of major morbidity and mortality, including the rate of anastomotic leak, similar to that in other series, both for open surgery and for MIEs. One patient, with a history of HBV infection but not liver cirrhosis, died 16 days post-surgery. There was no image evidence of liver cirrhosis or varicose veins at his initial evaluation. However, he had an episode of acute hepatitis during neoadjuvant concurrent chemoradiation therapy. The hepatitis was controlled before surgery. The Child score before surgery was B. Despite the high perioperative risk because of hepatitis, the patient urged us to do the surgery. During the laparoscopic portion, we saw that his liver was shrinking and that it had an uneven surface. Because the esophagectomy was finished, we were unable to discontinue the procedure. The operation was finished without any intraoperative problems, but the patient rapidly developed hepatic failure, a progressively elevated bilirubin level, and hemorrhage. Respiratory failure, anastomosis leakage, and sepsis soon developed as well.

The 3rd robotic arm permits self-controlled assistance.[12] It is very useful for retraction and exposure and thus dramatically reduces the assistant's work. Both for MIEs and for three-armed RAMIEs, 1 or even 2 experienced assistants are required for retraction, which ensures that the surgical table will be crowded. The assistant actually must be very attentive to prevent the robot arms from colliding with each other. With a four-armed RAMIME, we have never needed more than 1 assistant.

Technical Considerations

Avoid thermal injury

Sarkaria et al.[12] described an ultrasonic-energy-instrument-related thermal injury. They illustrated 2 thermal-injury-related tracheobronchial fistulas and suggested that a unipolar-energy instrument replace the ultrasonic-energy instrument. In our experience, both bipolar- and unipolar-energy instruments can also cause local thermal injury. The ultrasonic-energy instrument itself will not cause more thermal injury. We adapted the rotation force to build a tension plane when doing dissections. By rotating the ultrasonic shears away from viable tissue, most thermal injuries were avoided. Because the freedom of the ultrasonic-energy instrument is limited, greater skill is required to use it well and safely.

Greater gastric curve visualization

Sarkaria et al.[12] also described the difficulty of greater gastric curve visualization, a problem that caused several conversions to open surgery in their series. In the present study, however, this problem did not lead to any conversions, because we managed greater gastric curve visualization using the 3rd robotic arm retraction without a grasp. The double fenestrate grasp was routinely used on the 3rd robotic arm in this procedure. We grasped no tissue with it. Instead, we used its long instrument tip to retract the stomach in a parallel direction. Retraction was very useful in the body area; however, in the fundus area, it was not as useful because no downward retraction force can be applied without grasping. Thus, we managed the fundus area *via* the lesser curvature after the left gastric artery had been transected, which always worked. Therefore, we injured no stomachs because we grasped none. The circulation of the gastric conduit was always good. There is another critical trick for greater curve visualization. Do not place the camera port far above the umbilicus. The robotic camera cannot turn backward as it can in laparoscopy. In our experience, the umbilicus is the best site for the camera port.

Liver retraction

To manage the hiatal region, a good liver retraction is critical for a proper view. Traditionally, a liver retraction is done using a Nathanson liver retractor. A small puncture in the sub-xyphoid region is required to set up this instrument. However, the retractor is not necessary. We did the liver retraction using a simple handmade device composed of a straight needle, string, and a segment of a JP drain.[15] The liver was punctured about 2 cm from the liver border and hung on the peritoneal wall. This afforded us an excellent view of the hiatal region. We never encountered complications with this procedure. Moreover, liver-border circulation appeared to the naked eye to be much better than when using the Nathanson retractor.

Gastric conduit formation

For the past decade, a growing number of studies have described the benefits of a narrow gastric conduit. Instead of the gastric pull-up, a narrow tube-like gastric conduit has less food retention and a lower regurgitation rate. In the USA, Luketich et al.[16] reported a method of gastric conduit formation, and in Taiwan, Wang et al.[17] reported a practical and easier approach: cutting off the lesser curvature. We used a modified version of the latter. When cutting off the lesser curvature, we left a narrow stump at the gastric cardiac portion. We then pulled up the remnant portion of the lesser curvature together with the gastric conduit to the cervical incision. Because both the hiatus and thoracic inlet were wide open after the dissection, there was no resistance when we pulled it up. It was effective and time-

saving.

In summary, RAMIME with a four-arm platform is feasible. In comparison with McKeown MIE, the three-dimensional vision, camera stability, and the high degree of freedom together with the 3rd robotic arm suggest a promising future for RAMIME. Furthermore, because an esophagectomy takes a long time to complete, the comfortable sitting posture when doing RAMIME makes the procedure even more attractive to esophageal surgeons.

Conversely, the robot is a new surgical platform with some limitations because it requires a large workspace. It also takes some time to get used to the limitations of the robotic platform, e.g., limited contralateral arm maneuverability and collisions between robotic arms. With enough practice and understanding of the operating rules, a rational practice program that will remove most of the robot's drawbacks can be developed.

Additional long-term cohort studies are necessary to adequately evaluate patient outcomes for operations using the robot. Multicenter studies with larger and randomized study populations should confirm the strengths and weaknesses of RAMIME. Initial experiences have revealed results that are at least comparable to those of MIE. With good understanding of the robotic concepts and a good robotic team, RAMIME is worth trying. It has the great advantage of replacing at least one assistant, and initial outcomes indicate that RAMIME is feasible.

CONFLICTS OF INTEREST: None declared.

REFERENCES

1. Luketich J, Pennathur A, Catalano PJ, et al. Results of a phase II multicenter study of minimally invasive esophagectomy (Eastern Cooperative Oncology Group Study E2202). *J Clin Oncol.* 2009; 27: 4516.

2. Lazzarino AI, Nagpal K, Bottle A, Faiz O, Moorthy K, Aylin P. Open versus minimally invasive esophagectomy: trends of utilization and associated outcomes in England. *Ann Surg*. 2010; 252: 292-298. doi: 10.1097/SLA.0b013e3181dd4e8c

3. Talamini MA, Chapman S, Horgan S, Melvin WS. A prospective analysis of 211 robotic-assisted surgical procedures. *Surg Endosc.* 2003; 17: 1521-1524. doi: 10.1007/s00464-002-8853-3

4. Bodner J, Wykypiel H, Wetscher G, Schmid T. First experiences with the da Vinci operating robot in thoracic surgery. *Eur J Cardiothorac Surg.* 2004; 25: 844-851. doi: 10.1016/j.ejcts.2004.02.001

5. Dapri G, Himpens J, Cadiere GB. Robot-assisted thoracoscopic esophagectomy with the patient in the prone position. *J Laparoendosc Adv Surg Tech A.* 2006; 16: 278-285. doi: 10.1089/lap.2006.16.278

6. van Hillegersberg R, Boone J, Draaisma WA, Broeders IA, Giezeman MJ, Borel Rinkes IH. First experience with robot-assisted thoracoscopic esophagolymphadenectomy for esophageal cancer. *Surg Endosc.* 2006; 20: 1435-1439. doi: 10.1007/s00464-005-0674-8

7. Boone J, Schipper ME, Moojen WA, Borel Rinkes IH, Cromheecke GJ, van Hillegersberg R. Robot-assisted thoracoscopic oesophagectomy for cancer. *Br J Surg.* 2009; 96: 878-886. doi: 10.1002/bjs.6647

8. Kim DJ, Hyung WJ, Lee CY, et al. Thoracoscopic esophagectomy for esophageal cancer: feasibility and safety of robotic assistance in the prone position. *J Thorac Cardiovasc Surg*. 2010; 139: 53.e1-59.e1. doi: 10.1016/j.jtcvs.2009.05.030

9. Patriti A, Ceccarelli G, Ceribelli C, et al. Robot-assisted laparoscopic management of cardia carcinoma according to Siewert recommendations. *Int J Med Robot*. 2011; 7: 170-177. doi: 10.1002/rcs.385

10. Weksler B, Sharma P, Moudgill N, Chojnacki KA, Rosato EL. Robot-assisted minimally invasive esophagectomy is equivalent to thoracoscopic minimally invasive esophagectomy. *Dis Esophagus.* 2011; 25(5): 403-409. doi: 10.1111/j.1442-2050.2011.01246.x

11. Kernstine KH, DeArmond DT, Shamoun DM, Campos JH. The first series of completely robotic esophagectomies with three-field lymphadenectomy: initial experience. *Surg Endosc.* 2007; 21: 2285-2292. doi: 10.1007/s00464-007-9405-7

12. Sarkaria IS, Rizk NP, Finley DJ, et al. Combined thoracoscopic and laparoscopic robotic-assisted minimally invasive esophagectomy using a four-arm platform: experience, technique and cautions during early procedure development. *Eur J Cardiothorac Surg.* 2013; 1: 1-9. doi: 10.1093/ejcts/ezt013

13. Trotti A, Colevas AD, Setser A, et al. CTCAE v3.0: development of a comprehensive grading system for the adverse effects of cancer treatment. *Semin Radiat Oncol.* 2003; 13: 176-181. doi: 10.1016/S1053-4296(03)00031-6

14. U.S. Department of Health and Human Services, National Institutes of Health, National Cancer Institute. Common Terminology Criteria for Adverse Events (CTCAE) Version 4.0. Website: http://www.eortc.be/services/doc/ctc/CTCAE_4.03_2010-06-14_QuickReference_5x7.pdf. 2010; Accessed 2013.

15. Huang CK, Lo CH, Asim S, Houng JY, Huang SF. A novel

technique for liver retraction in laparoscopic bariatric surgery. *Obes Surg*. 2011; 21: 676-679. doi: 10.1007/s11695-010-0191-2

16. Luketich JD, Alvelo-Rivera M, Buenaventura PO, et al. Minimally invasive esophagectomy: outcomes in 222 patients. *Ann Surg*. 2003; 238: 486-494.

17. Wang BY, Tsao LC, Cheng CY, Lin CH, Shih CS, Liu CC. Experiences with a simple laparoscopic gastric tube construction. *J Cardiothorac Surg*. 2013; 8: 14. doi: 10.1186/1749-8090-8-14