

Case Report

Corresponding author

Suzanne F. van Rijn, MD

Department of Orthopaedic Surgery

Amphia Hospital - Breda

Hoogstraat 121V

3011 PL Rotterdam

The Netherlands

Tel. +31 6 467 976 60

E-mail: sfvanrijn@gmail.com

Volume 2 : Issue 2

Article Ref. #: 1000EMOJ2128

Article History

Received: August 30th, 2016

Accepted: September 26th, 2016

Published: September 26th, 2016

Citation

van Rijn SF, Kaas L, Beumer A, Boer R. A distal clavicle fracture with unusual displacement of the medial part. *Emerg Med Open J.* 2016; 2(2): 39-41. doi: [10.17140/EMOJ-2-128](https://doi.org/10.17140/EMOJ-2-128)

Copyright

©2016 van Rijn SF. This is an open access article distributed under the Creative Commons Attribution 4.0 International License (CC BY 4.0), which permits unrestricted use, distribution, and reproduction in any medium, provided the original work is properly cited.

A Distal Clavicle Fracture With Unusual Displacement of the Medial Part: A Case Report

Suzanne F. van Rijn, MD^{1*}; Laurens Kaas, MD, PhD²; Annechien Beumer, MD, PhD¹; Ronald Boer, MD¹

¹Department of Orthopaedic Surgery, Amphia Hospital, Breda, The Netherlands

²Department of Orthopaedic Surgery, Antonius Hospital Nieuwegein/Utrecht, The Netherlands

ABSTRACT

Introduction: A 22-year-old man came to the emergency department after a fall on right shoulder. The radiographs showed a distal clavicle fracture with apparent disruption of the acromioclavicular joint (AC-joint). The CT-scan however showed an intact AC-joint with a Neer type IIb fracture pattern, except for a dislocation of the medial fragment to dorsocaudal.

Intervention: Ten days after trauma the patient was treated with open reduction and internal fixation using a hook plate.

Outcome: Six weeks after surgery the patient had no pain and full range of motion of the arm.

Discussion: There are two ways to classify a distal clavicle fracture; the Craig's classification or the Neer classification. In both classifications there is the medial part of the clavicle is elevated in a type IIb distal clavicle fracture. The X-ray in this case was misleading, appearing as a disruption of the AC-joint. In this case there probably was a blow to the shoulder and the medial part of the clavicle was pushed caudally and got captured under the distal fragment of the clavicle. There are two systematic reviews and one meta-analysis about the treatment of a distal clavicle fracture. They all state that a hook plate is the most frequently used fixation technique, although it seems to have the highest complication rate.

INTRODUCTION

A distal clavicle fracture is a relatively uncommon injury.¹ When a distal clavicle fracture occurs, there is usually elevation of the medial part of the clavicle as the lateral fragment is held in place with the acromioclavicular (AC) capsule. Hereby, we present a case of a 22-year-old male with an unusual fracture dislocation of the distal clavicle.

Patient

A 22-year-old male presented himself at the emergency room with pain at the right shoulder after a motor-bike accident. He had fallen on his right shoulder when driving approximately 35 km/h. On physical examination, we found elevation of the distal clavicle with displacement of the medial part caudally. There was pain on palpation. The piano key test was negative. The skin was intact and without tension. Abduction and flexion of the arm were painful. Neurovascular examination of the arm was normal.

The radiographs showed a distal clavicle fracture with an apparent disruption of the AC joint (Figure 1). A CT-scan (Computed Tomography) was obtained because physical examination and the radiographs did not comply. The CT-scan showed an intact AC-joint with a Neer type II B fracture pattern, except for a dislocation of the medial fragment to dorso-caudal (Figure 2).²

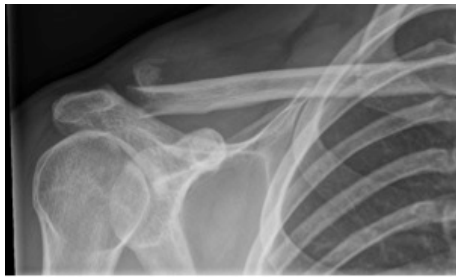

Figure 1: Anteroposterior (AP) radiograph of the right clavicle.

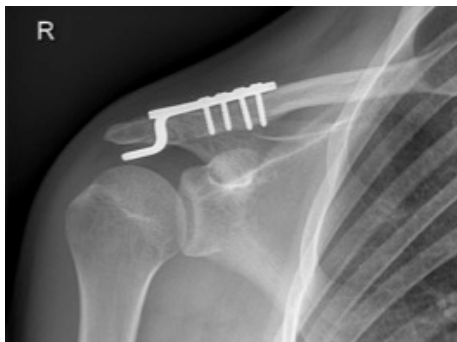

Figure 3: AP radiograph of the right clavicle six weeks after open reduction and internal fixation using a hook plate.

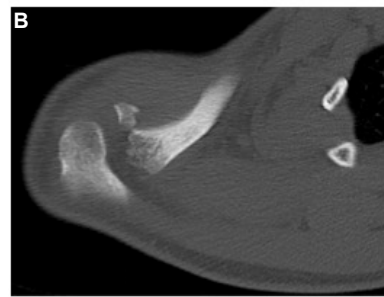
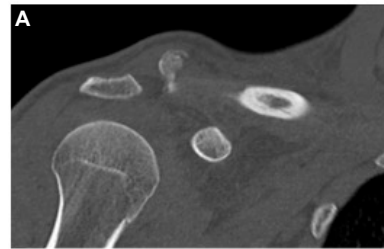


Figure 2: (A) CT-scan of the right clavicle showing an intact AC joint and (B) dorsocaudal displacement of the medial part of the clavicle.

Intervention

Ten days after the initial trauma, the patient was treated with open reduction and internal fixation using a hook plate (Figure 3). A dorsocaudal displacement of the medial part of the clavicle was seen. The fracture was reduced using reduction clamps and the hook plate was placed. Due to the small distal part, only screws medial to the fracture was placed. After the surgery the patient was allowed 90 degrees abduction and forward flexion of the right arm for six weeks.

Outcome

Six weeks post-operative the patient had no pain and full range of motion of the arm. He reported some loss of muscle strength with abduction. The hook plate will be removed in three months.

RELEVANT LITERATURE/DISCUSSION

A fracture of the distal clavicle is relatively uncommon. It accounts for approximately 10-15% of all fractures of the clavicle.¹ There are two ways to classify a distal clavicle fracture: The Craig's classification or the Neer classification.^{2,3} In both of these a type II distal clavicle fracture is unstable, where type II A occurs medial to the coronoid and trapezoid ligament and type II B occurs medial or lateral to the trapezoid ligament where either the coronoid ligament is torn exclusively or both ligaments are torn. In both classifications the medial part of the clavicle is elevated. None of the classification describes dorsocaudal displacement of the clavicle. In this case there was probably a blow to the shoulder, which pushed the medial part of

the clavicle caudally where it became captured under the distal fragment. The X-ray in this case was misleading, appearing as a disruption of the AC joint. To our knowledge, this has never been published before. We obtained a CT-scan because the X-ray did not comply with physical examination. The risk of a misleading X-ray is either malunion of the clavicle in conservative treatment, which can lead to shoulder complaints or unexpected finding during surgery, which can complicate the operation.⁴

Due to the risk of non-union and the young age of the patient an operation was planned. Although this type of fracture (and the operative possibilities) is already described by Neer in 1963, till this date there is no universally agreed standard operative procedure for displaced distal clavicle fractures.⁵ We found two reviews and a meta-analyses concerning the treatment of a distal clavicle fracture. Oh et al, found no statistical differences in union/non-union rates but more complications in the group treated with a hook plate or Kirschner wires in combination with Tension Band Wiring (TBW).⁶ They advised using intramedullary screw fixation, CC stabilization or interfragmentary fixation. Although they do state that the results should be interpreted with caution, 'as the validity of the observational studies is limited by the lack of a control group (case series), imbalances between the comparison groups because of the lack of randomization (retrospective case control studies), and potentially biased assessment of outcome measures due to the lack of blinding'. Sambandam et al⁵ stated that all techniques give good functional outcomes, but flexible and semi-rigid fixation like open or arthroscopic coracoclavicular (CC) fixation, tension banding with sutures and coracoclavicular screws seem to avoid most of the implant related secondary complications.⁵

Also in this review, they state that the level of evidence is low. Stegeman et al⁷ stated that a hook plate is the most frequently used fixation technique, although it has the highest complication rate compared to intramedullary fixations and sutures.

RECOMMENDATIONS

In case of inconclusive physical examination or radiographs of a distal clavicle fracture, we advise to obtain a CT-scan. There is no optimal treatment for distal clavicle fractures. We advise a critical assessment of individual case. Until more research is undertaken, the best treatment is the surgical technique in which the operating surgeon is most experienced and familiar with.

CONFLICTS OF INTEREST

The authors declare that they have no conflicts of interest.

CONSENT

Since we did not add photographs in which the patient was recognizable, we did not obtain informed consent.

REFERENCES

1. Nordqvist A, Petersson C. The incidence of fractures of the clavicle. *Clin Orthop Relat Res*. 1994; 300: 127-132. Web site. http://journals.lww.com/corr/Abstract/1994/03000/The_Incidence_of_Fractures_of_the_Clavicle.16.aspx. Accessed August 29, 2016.
2. Neer CS. Fractures of the distal third of the clavicle. *Clin Orthop Relat Res*. 1968; 58: 43-50.
3. Craig E. Fractures of the clavicle. In: Rockwood CA Jr, eds. *The Shoulder*. Philadelphia, PA, USA: W.B. Saunders; 1998: 428-482.
4. Wang XH, Guo WJ, Li AB, et al. Operative versus nonoperative treatment for displaced midshaft clavicle fractures: A meta-analysis based on current evidence. *Clinics (Sao Paulo)*. 2015; 70(8): 584-592. doi: [10.6061/clinics/2015\(08\)09](https://doi.org/10.6061/clinics/2015(08)09)
5. Sambandam B, Gupta R, Kumar S, Maini L. Fracture of distal end clavicle: A review. *J Clin Orthop Trauma*. 2014; 5(2): 65-73. doi: [10.1016/j.jcot.2014.05.007](https://doi.org/10.1016/j.jcot.2014.05.007)
6. Oh JH, Kim SH, Lee JH, Shin SH, Gong HS. Treatment of distal clavicle fracture: A systematic review of treatment modalities in 425 fractures. *Arch Orthop Trauma Surg*. 2011; 131(4): 525-533. doi: [10.1007/s00402-010-1196-y](https://doi.org/10.1007/s00402-010-1196-y)
7. Stegeman SA, Nacak H, Huvenaars KH, Stijnen T, Krijnen P, Schipper IB. Surgical treatment of Neer type-II fractures of the distal clavicle: A meta-analysis. *Acta Orthop*. 2013; 84(2): 184-190. doi: [10.3109/17453674.2013.786637](https://doi.org/10.3109/17453674.2013.786637)