


Case Report

Citrobacter Freundii Skin Infection in an Immunocompetent Subject Simulating Varicella: A Treatment-Resistant Case

 Savané Moussa, MD^{1,2*}; Gassama Mamadou, MD¹; Guindo Binta, MD¹; Diakité Mamoudou, MD¹; Mukendi N. Yannick, MD¹; Keita Alimata, MD¹; Fofana Youssouf, MD³; Dissa Labassou, MD¹; Soumah M. Maciré, MD²; Cissé Mohamed, MD²; Faye Ousmane, MD, PhD¹

¹Hospital of Dermatology of Bamako (HDB), B. P. 251, Bamako, Mali

²Faculty of Health Sciences and Techniques, Conakry, Guinea

³Sominé Dolo Hospital of Mopti, Mopti, Mali

Corresponding author*Savané Moussa, MD**

Hospital of Dermatology of Bamako (HDB), B. P. 251, Bamako, Mali; Faculty of Health Sciences and Techniques, Conakry, Guinea; Tel. 0022399335376;

E-mail: moussasavan@gmail.com

Article information

Received: February 1st, 2023; **Revised:** February 17th, 2023; **Accepted:** February 20th, 2023; **Published:** February 28th, 2023

Cite this article

Moussa S, Mamadou G, Binta G, et al. *Citrobacter freundii* skin infection in an immunocompetent subject simulating varicella: A treatment-resistant case. *Dermatol Open J.* 2023-2024; 8(1): 1-3. doi: [10.17140/DRMTOJ-8-152](https://doi.org/10.17140/DRMTOJ-8-152)

ABSTRACT

Citrobacter spp infections in immunocompetent subjects are rare and mainly involve the urinary and respiratory tracts. We report a case of *Citrobacter freundii* skin infection in an immunocompetent patient simulating varicella and having resisted empirical treatment of common bacterial skin infections on 3 occasions. The patient was 26-years-old and worked in a mining area in Kayes, Mali. He had no previous medical or surgical history and consulted for diffuse papulopustules on the integument, simulating chickenpox, for which he had received empirical treatments of common bacterial skin infections without success. In view of the persistence and appearance of new lesions, he consulted us on 2nd November 2021, where a bacteriology showed *Citrobacter freundii*. The patient was treated with ceftazidime and gentamycin with success (according to the patient). *Citrobacter spp* are facultative anaerobic Gram-negative bacilli of the Enterobacteriaceae family, frequently found in water, soil, food and the intestines of animals and humans. They are known to cause a wide spectrum of infections affecting the urinary tract, liver, biliary tract, peritoneum, intestines, bone, respiratory tract, endocardium, wounds, soft tissue, meninges and bloodstream in immunocompromised subjects. Our case is atypical in its presentation, immunocompetent subject, clinical form simulating chickenpox without extracutaneous involvement and which raised the resistance of opportunistic germs to antibiotics.

Keywords

Citrobacter freundii; Skin infection; Immunocompetent subject; Mali.

INTRODUCTION

Citrobacter infections in immunocompetent subjects are rare and occur mainly in the urinary and respiratory tracts.¹ Of all *Citrobacter species*, *Citrobacter freundii* is the most frequently isolated group in these patients.² A mortality rate of 6.8% has been reported in patients hospitalized with *Citrobacter* infection, but it can increase dramatically to 17.8-56% with *Citrobacter bacteremia*. There is growing public concern about longer hospital stays and higher antibiotic costs because of the recent emergence of multidrug-resistant strains of *Citrobacter*.³ We report a case of *Citrobacter* skin infection in a treatment-resistant immunocompetent subject.

OBSERVATION

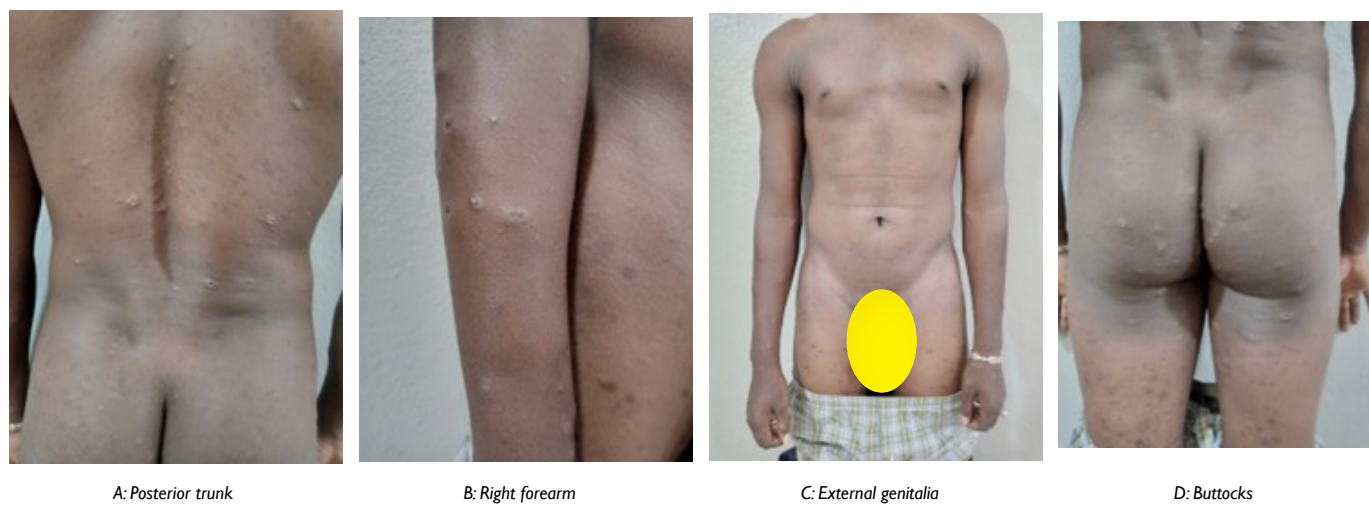
A 26-year-old Malian patient, working in a mining area in Kayes,

with no particular medical or surgical history, consulted for diffuse papulo-pustules on the integument, for which he had consulted more than 3 times in local medical centres where the diagnosis of chickenpox had been made and each time he had received treatment (aseptic, antibiotics and antipyretics) which had led to slight improvement.

In view of the persistence and appearance of new lesions over the past 3-weeks, he consulted the dermatology hospital in Bamako on 2nd November 2021. On examination, he was in good general condition with a fever of 38.7 °C, a body mass index (BMI) of 20 and other normal vital parameters.

On the skin, there were papulo-pustules, some with central umbilication, others ulcerated, erosive and coalescent, diffuse. These lesions were predominant on the posterior trunk, forearms, buttocks and external genitalia. There were also pigmented scar-

Figure 1. Papulo-pustules, some with Central Umbilication, others Ulcerative, Erosive and Coalescing, and Pigmented Scars on the Sites of Old Lesions



ring lesions at the sites of former lesions. The rest of the mucophanerian examination and other systems were unremarkable (Figure 1).

The blood count, the transaminases, the creatinine, the blood sugar, the treponemal and viral serology (hepatitis B and C viruses, human immunodeficiency virus (HIV)) were normal but no polymerase chain reaction (PCR) was carried out for monkeypox. Urine cytobacteriological examination and abdominopelvic ultrasound were also normal. Pus collection (from a lesion on the buttocks, a lesion on the right forearm, and one on the external genitalia) for bacteriological analysis revealed the presence of *Citrobacter freundii* and the susceptibility test showed sensitivity to ceftazidime and gentamycin. The evolution was favourable after 7-days of treatment according to the patient (by telephone) who did not return for his check-up.

DISCUSSION

Citrobacter infections are rare. They usually affect patients with impaired host defenses.⁴ We report a case of *Citrobacter freundii* skin infection in an immunocompetent patient who was resistant to empirical treatments of common bacterial skin infections. *Citrobacter spp* are facultative anaerobic Gram-negative bacilli of the Enterobacteriaceae family,¹ commonly found in water, soil, food, and intestines of animals and humans.⁵

One case was atypical in its clinical presentation, simulating chickenpox, but was clinically ruled out because chickenpox is never recurrent and these lesions usually have a cephalocaudal progression. Reported cases of *Citrobacter* infecting the skin have had the following clinical presentations: folliculitis, cellulitis, urticaria, gangrenosum-like ecthyma, ulcers and necrotizing fasciitis.² Previously recognized as low virulence environmental contaminants or colonizers, they are now known to cause a broad spectrum of infections affecting the urinary tract, liver, biliary tract, peritoneum, intestines, bone, respiratory tract, endocardium, wounds, soft tissue, meninges and bloodstream,³ however, we did not observe

any extracutaneous involvement in the patient on the clinical and paraclinical level. The comorbidities that could favor the occurrence of *Citrobacter* infection, notably malignant tumor, arterial hypertension, diabetes mellitus, hepatobiliary stones, and chronic renal disease, were not found in the patient. Our patient was not also under long-term immunosuppressive treatment which could also favor the occurrence of this infection as reported by Ferranti et al¹ in a patient suffering from pemphigus and under immunosuppressive treatment who presented an ecthyma gangrenosum with *Citrobacter freundii*. These enterobacteriaceae may possess an inducible *AmpC* gene, which codes for a beta-lactamase leading to potential antibiotic failure,^{1,6} Lavigne et al⁷ reported in their study that 28.9% of *Citrobacter spp* were resistant to extended-spectrum cephalosporins. After antibiotic susceptibility testing, our patient was treated with ceftazidime and gentamycin, the latter reported to be effective against these enterobacteriaceae in the literature.⁸

CONCLUSION

It is important for clinicians to be aware of both possible atypical presentations of certain bacterial infections, and of antibiotic resistance. Bacteriology and antibiotic susceptibility testing are essential in cases of bacterial infections that are thought to be common and resistant to empirical treatments.

CONSENT

The authors have received written informed consent from the patient.

CONFLICTS OF INTEREST

The authors declare that they have no conflicts of interest.

REFERENCES

1. Ferranti M, Cicogna GT, Sattin A, Alaibac M. *Citrobacter freundii* sepsis in an immunosuppressed patient with pemphigus vul-

- garis. *BMJ Case Rep.* 2018; 11(1): e227091. doi: [10.1136/bcr-2018-227091](https://doi.org/10.1136/bcr-2018-227091)
2. Whalen JG, Mully TW, English JC. Spontaneous *Citrobacter freundii* infection in an immunocompetent patient. *Arch Dermatol.* 2007; 143: 124-125. doi: [10.1001/archderm.143.1.124](https://doi.org/10.1001/archderm.143.1.124)
3. Liu L-H, Wang N-Y, Wu AY-J, Lin C-C, Lee C-M, Liu C-P. *Citrobacter freundii* bacteremia: Risk factors of mortality and prevalence of resistance genes. *J Microbiol Immunol Infect.* 2018; 51: 565-572. doi: [10.1016/j.jmii.2016.08.016](https://doi.org/10.1016/j.jmii.2016.08.016)
4. Chlossberg D, Ricci JA, Fugate JS. Dermatologic manifestations of *Citrobacter* septicemia. *J Am Acad Dermatol.* 1981; 5: 613-615. doi: [10.1016/s0190-9622\(81\)80042-4](https://doi.org/10.1016/s0190-9622(81)80042-4)
5. Lipsky BA, Hook EW III, Smith AA, Plorde JJ. *Citrobacter* infections in humans: Experience at the Seattle Veterans Administration Medical Center and a review of the literature. *Rev Infect Dis.* 1980; 2: 746-760. doi: [10.1093/clinids/2.5.746](https://doi.org/10.1093/clinids/2.5.746)
6. Meini S, Tascini C, Cei M, Sozio E, Rossolini GM. AmpC β -lactamase-producing Enterobacterales: What a clinician should know. *Infection.* 2019; 47(3): 363-375. doi: [10.1007/s15010-019-01291-9](https://doi.org/10.1007/s15010-019-01291-9)
7. Lavigne JP, Defez C, Bouziges N, Mahamat A, Sotto A. Clinical and molecular epidemiology of multidrug-resistant *Citrobacter* spp. infections in a French university hospital. *Eur J Clin Microbiol Infect Dis.* 2007; 26(6): 439-441. doi: [10.1007/s10096-007-0315-3](https://doi.org/10.1007/s10096-007-0315-3)
8. Chen C, Chen Y, Wu P, Chen B. Update on new medicinal applications of gentamicin: Evidence-based review. *J Formos Med Assoc.* 2014; 113: 72-82. doi: [10.1016/j.jfma.2013.10.002](https://doi.org/10.1016/j.jfma.2013.10.002)